Postmortem Inspection

Objectives

1. Define the purpose of postmortem inspection.
2. Identify the statutes that provide FSIS the authority for conducting postmortem inspection.
3. Identify the regulations that cover postmortem inspection.
4. List the directives that provide instructions on conducting postmortem inspection procedures.
5. Identify the establishment responsibilities with regard to postmortem inspection.
6. Describe the process of conducting postmortem inspection procedures.
7. Define how the establishment must dispose of condemned product.

Introduction

Postmortem inspection covers the inspection of the carcasses and parts of meat used for human food. It takes place after ante mortem inspection, and after the animal has been slaughtered, thus the term -postmortem, meaning after death in Latin. Postmortem inspection covers the steps in the slaughter process that begin at stunning and end at the step where the carcass is placed in the cooler.

The purpose of postmortem inspection is to protect the public health by ensuring that the carcasses and parts that enter commerce are wholesome, not adulterated, and properly marked, labeled, and packaged. This means that any carcasses or parts that are unwholesome or adulterated, and thereby unfit for human food, do not enter commerce. In performing inspection methods, making regulatory decisions, documenting findings, and taking enforcement actions when appropriate, in relation to postmortem inspection we are guided by the following statutes, regulations, directives, and notices.

Statutes

The statutory authority for postmortem inspection is as follows:

Livestock:

FMIA Sec. 604*. "Postmortem examination of carcasses and marking or labeling; destruction of carcasses condemned; reinspection. For the purposes hereinbefore set forth the Secretary shall cause to be made by inspectors appointed for that purpose a postmortem examination and inspection of the carcasses and parts thereof of all cattle, sheep, swine, goats, horses, mules, and other equines to be prepared at any slaughtering, meat-canning, salting, packing, rendering, or similar establishment in any State, Territory, or the District of Columbia as articles of commerce which are capable of use as human food; and the carcasses and parts thereof of all such animals found to be not adulterated shall be marked, stamped, tagged, or labeled as "Inspected and passed;" and said inspectors shall label, mark, stamp, or tag as "Inspected and condemned" all carcasses and parts thereof of animals found to be adulterated; and all carcasses and parts thereof thus inspected and condemned shall be destroyed for food*

purposes by the said establishment in the presence of an inspector, and the Secretary may remove inspectors from any such establishment which fails to so destroy any such condemned carcass or part thereof, and said inspectors, after said first inspection, shall, when they deem it necessary, reinspect said carcasses or parts thereof to determine whether since the first inspection the same have become adulterated, if any carcass or any part thereof shall, upon examination and inspection subsequent to the first examination and inspection, be found to be adulterated, it shall be destroyed for food purposes by the said establishment in the presence of an inspector, and the Secretary may remove inspectors from any establishment which fails to so destroy any such condemned carcass or part thereof."

Regulations

The regulations that cover postmortem inspection for livestock are as follows:

9 CFR 310.2 – States that the establishment must have a system that is used to identify livestock carcasses and parts to be used in the preparation of meat food products or in medical products (e.g., head, tail, tongue, thymus, viscera, blood, and other parts) as being derived from the particular animal involved until the postmortem inspection of the carcass and parts is completed.

9 CFR 310.3 – States that any carcasses, organs, or parts in which any lesion or other condition is found that might render the meat or any part unfit for human food, or otherwise adulterated must be retained for veterinary disposition. The identity of the carcass, organs, and parts must be maintained until final disposition has been completed. Retained carcasses shall not be washed or trimmed unless authorized by FSIS.

9 CFR 310.4 – Identifies that U.S. Retained tags will be used to temporarily identify any carcasses, organs, or parts retained for veterinary disposition. These tags can only be removed by an FSIS employee.

9 CFR 310.5 – States that any carcass or part found upon final inspection to be unsound, unhealthful, unwholesome, or otherwise adulterated shall be conspicuously marked as U.S. Condemned. These carcasses or parts must remain in the custody of FSIS and disposed of according to the regulations before the close of the day upon which they are condemned.

9 CFR 310.6 – States that carcasses and parts that are passed for cooking only shall be marked U.S. Passed for Cooking, and must remain in the custody of FSIS until they are cooked according to 9 CFR 315.

9 CFR 310.8 – Describes passing and marking carcasses and parts. Those that are found to be sound, healthful, wholesome and otherwise not adulterated are marked U.S. Inspected and Passed. Those that show localized lesions are passed for food or for cooking, and the U.S. Retained tag is attached until the affected tissue is removed and condemned.

9 CFR 310.18(a) States that carcasses, organs, and other parts shall be handled in a sanitary manner to prevent contamination with fecal material, urine, bile, hair, dirt, or foreign matter; however if contamination occurs it shall be promptly removed in a manner satisfactory to the inspector.

9 CFR 310.21 – Covers residues in postmortem inspection. We will address this in a separate section of the training.

9 CFR 310.25 – Covers contamination of livestock carcasses and parts with microorganisms; process control verification criteria and testing; and pathogen

reduction standards. You will learn about this is more detail when you attend the Inspection Methods class.

9 CFR 311 – Covers diseased and otherwise adulterated carcasses and parts.
9 CFR 314 – Covers how establishments must handle condemned and inedible carcasses and parts.
9 CFR 315 – Covers rendering or other disposal of carcasses and parts, and product that has been passed for cooking during postmortem inspection.

Directives

The Directives that cover the procedures for postmortem inspection are found in the 6000 series. Following are some examples of these Directives:

FSIS Directive 6100.2, Post-Mortem Livestock Inspection
FSIS Directive 6100.4, Verification Instructions Related to Specified Risk Materials
FSIS Directive 6240.1, Inspection, Sampling, and Disposition of Animals for Tuberculosis
FSIS Directive 6420.2, Verification of Procedures for Controlling Fecal Material, Ingesta and Milk in Slaughter Operations
FSIS Directive 6810.2, Marking Carcasses and Products (Meat)

The regulations and directives provide the instructions for performing inspection procedures, making regulatory determinations, documenting noncompliance when appropriate, and taking regulatory actions.

Establishment Responsibilities

The primary responsibility of the establishment is to ensure that its production processes result in the safe and wholesome product. In addition, FSIS regulations outline some responsibilities of the establishment that are specifically related to postmortem inspection. These responsibilities include

Sanitary practices in preparing the carcass for postmortem inspection,
Presenting carcasses and parts for inspection in a specified manner (called presentation), and
Facility requirements at the inspection stations.

In general, the establishment's procedures to prepare livestock for inspection must take place in sanitary conditions and must use sanitary procedures to prevent contamination of the carcasses and parts (9 CFR 310.18, and 416). For example, during livestock slaughter, the establishment must use sanitary dressing procedures to remove and skin the head, dehide or dehair and eviscerate the carcass, wash the head and carcass, and split and trim the carcass.

The establishment must also ensure that the carcasses are presented for inspection in a specified manner (9 CFR Part 307). For example, they must be hung on the line in a specified manner and spaced appropriately. The organs of livestock must be displayed in a specified order so that the inspector does not have to spend time locating them before he or she performs inspection procedures. Proper presentation helps to ensure

consistent and accurate inspection. There are variations in the ways in which an establishment will present carcasses and parts for inspection. You will learn about these in the establishment from your supervisor and experienced inspectors.

The establishment is also responsible for providing appropriate inspection stations that meet regulatory requirements (9 CFR 307.2). The requirements vary depending on the type of equipment used at the establishment. For example, in large livestock slaughter establishments, there may be separate inspection stations for heads, viscera, and carcasses. However, if you are assigned to a very small establishment, inspection for all of the regulatory requirements may take place in one location. Regardless of the number or placement of the inspection stations, the following conditions must be provided by the establishment.

Adequate space for conducting inspection (e.g., the size and height of the on line inspection station) (9 CFR 307.2(m) (1))
Adequate lighting for conducting inspection (9 CFR 307.2(b), 9 CFR 307.2(m) (2))
Hand rinsing facilities to ensure that sanitary conditions are maintained (9 CFR 307.2(m) (3))
Condemned containers for disposal of condemned carcasses or parts (9 CFR 307.2(e))

These requirements are necessary to ensure that there are adequate provisions to allow for inspection duties to be conducted appropriately.

Inspection Responsibilities

During this section of the training, we will cover postmortem inspection responsibilities and procedures.

There are three possible disposition outcomes at postmortem inspection.

(1) *passed*, and thus eligible to receive the marks of inspection (9 CFR 310.8);
(2) *retained*, which must be retained until final disposition has been made (9 CFR 310.3); and
(3) *condemned,* which is not eligible to receive the marks of inspection and cannot enter commerce (9 CFR 310.5).

You will be responsible for identifying carcasses and parts that are retained for final disposition. The final determination is made by the veterinarian whether to pass or condemn a carcass and its associated parts. The primary guiding principle is whether the carcass, organ, or part is adulterated, or whether it is wholesome and fit for human food.

Sanitation

You and all other inspection personnel must always maintain proper hygiene when conducting inspection procedures. This is required by the regulations in 9 CFR 416.5. In most cases, the establishment will have a set of written requirements, such as standard operating procedures, that are required for establishment employees. For example, they may include requirements for employee hygiene such as hand washing, hair and beard

nets, and using foot baths when moving between edible and inedible areas of the establishment. You must meet or exceed those standards. As an FSIS employee, you are expected to meet or exceed the standards set by the establishment for proper hygiene while conducting inspection procedures. In addition, off line inspectors are responsible for verifying that the establishment is preparing the carcass and parts in a sanitary manner that meets the applicable regulatory requirements. This includes ensuring that the equipment, utensils, or any other such item used in preparing the carcass and parts are sanitary, and that the conditions in the establishment are sanitary. The establishment is required to have and to follow a set of procedures to maintain sanitary operations. The regulatory requirements for sanitation are found in the Sanitation Performance Standards (SPS) and the Sanitation Standard Operating Procedures (Sanitation SOPs) that are in 9 CFR 416.

Work Safety Considerations

There are a number of safety considerations that you must observe. T h e following is a brief overview of safety considerations. This list is not complete, but will raise your level of awareness about the number of safety issues you must consider while working in a slaughter establishment. Your supervisor will provide you with more specific instructions which you must follow.

Head gear

Protective helmets are important for your personal safety. A helmet can protect you from minor head lacerations and contusions, and may provide protection from a potentially fatal head injury. Do not enter a work area without your protective helmet.

Foot gear and gait

Many of the walking surfaces in a livestock establishment are very slippery. Wearing appropriate foot gear with a positive traction safety sole is important. Learn to walk in a way that you have maximum traction with each step. When walking on any elevated structure or stairs, be sure your footing is secure, and use handrails for additional support.

Clothing

Select durable, well-fitting clothing that allows you to move comfortably on the job. Loose fitting clothing may tangle in moving equipment or machinery. Personal comfort helps contribute to mental alertness.

Use of knifes

Learn the principles of keeping your knife sharp. Knives may be used by inspectors to expose deeper tissues that have been removed from the evisceration line and placed onto a stationary retain rack. A dull knife may result in slipping, which can cause injury to you or to another person working nearby. You can tell when your knife is dull because the incisions will have ragged and uneven edges and you will feel you have to -saw rather than slice cleanly. Never attempt to catch a falling knife. Step back to avoid injury.

Mechanized platforms

If your work requires you to use a mechanized platform, always take time to stabilize your footing and to grasp a safe hand hold firmly before activating the power lift to raise or lower the platform.

Hot pipes

Steam and water pipes are necessary equipment at many locations in the establishment. Take note of their location and avoid contact with them to reduce the risk of burns or other injuries.

Jewelry

As an FSIS employee, you are required to meet or exceed the standards for employee hygiene set for establishment employees. Most establishments have policies that prohibit the wearing of jewelry because of safety considerations. Jewelry provides a location for microorganisms to accumulate. Jewelry can also become caught in machinery, resulting in the loss of fingers or of a limb.

Personal health and safety

It is important to pay close attention to personal hygienic practices while handling diseased carcasses and parts during postmortem inspection. Avoid any unnecessary handling of this material. Rinse your hands often while you are handling it. Thoroughly wash your hands with soap and water as you depart your postmortem inspection station. Dry your hands with a disposable towel. Open cuts must be covered with a waterproof bandage. They may become infected if not kept clean and dry, and they have the potential of contaminating product once this occurs. A glove can be worn as protection for a hand wound.

Doorways and corridors

The safest procedure to follow while walking through doorways and corridors is to follow the driving rule and keep to your right. Be aware that mechanized doors may be activated by someone on the other side of the door.

Observing operations

Always make sure that others are aware of your presence whenever you are observing operations. Try not to startle others, as this could cause an accident. Many people become distracted when their work is observed closely. This distraction may cause an accident. Do not allow other employees to throw materials or play games around you, as this is an unsafe and unprofessional practice.

Power driven trucks and forklifts

Be aware of your surroundings when moving through the establishment. Make way for any power driven vehicles, such as forklifts, to reduce the risk of injury.

Ammonia fumes

Ammonia is frequently used in slaughter establishments. There are guidelines for using ammonia. Ammonia fumes in high concentration can be deadly. If the fumes become strong enough to cause your eyes to water, you should leave the area immediately and warn others of the danger.

Electricity

Be aware that there may be a number of electrical hazards that exist within the establishment. Be alert to these potential hazards.

Cleaning chemicals and compounds

Some cleaning chemicals and compounds are highly acid or alkaline, and prepared under pressure. Some of these materials are capable of burning skin and eyes. If you are accidentally splashed with this type of material, immediately flush the affected area with cold water. Avoid inhaling the fumes of these cleaners, as they may damage lungs.

Hearing protection

Hearing protection is required when noise levels exceed 85 decibels since noise at or above this level can cause irreversible hearing loss. A current FSIS Form 4791-20, Record of Noise Levels, must be posted on the government bulletin board at each official establishment. The following types of hearing protection devices may be issued: ear plugs, ear muffs, or sound-ban protectors. Hearing protection will need to be replaced periodically.

In case of accidents

If an accident occurs, notify your immediate supervisor as quickly as possible. Your supervisor will help to ensure you receive proper care and will assist you in preparing a report describing the accident.

Definitions

Following are definitions of some common terms used in postmortem inspection.

Meat – The muscle that is on the skeleton or that is found in the tongue, diaphragm, heart, and esophagus.

Meat byproduct – Any part other than meat capable of use as human food derived from cattle, sheep, swine, or goats.

Edible – Product intended for use as human food.

Inedible – Adulterated, uninspected, or not intended for use as human food. Some examples of inedible and condemned materials from cattle include manure, dead animals, blood, hair, pizzles, hooves, stomachs and intestines with contents, and

lungs. It also includes any product that has been condemned as a result of inspection. Any of these products that have the appearance of edible product must be designated as inedible so that it will not be confused with edible product while it is in the establishment, and must be made obviously unfit for human food before it leaves the official premises of the establishment.

Offal – Parts that are removed from the skeletal meat. Edible offal includes meat and tissues boned from the head as well as the heart, liver, spleen, and other viscera. Inedible offal is all other parts of the animal that are not saved for distribution to consumers. Edible and inedible offal varies from establishment to establishment. Some examples of edible offal parts of cattle include beef head meat, cheek meat, lips, tongue, liver, heart, spleen, weasand, bladder, and sweetbreads. Some examples of edible offal parts of swine include pork brains, ears, cheeks, tongues, lips, snouts, giblet meat, hearts, spleens, stomachs, intestines, kidneys, tails, feet, and jowls.

Byproducts – Edible byproducts may include items derived from the viscera, head, tail, etc. (e.g., pigs knuckles). The type of byproducts included varies from establishment to establishment. (See Appendix for examples of byproducts.)

General Methods of Postmortem Inspection

The general methods you will use to detect diseases, abnormalities, and contamination is organoleptic inspection which involves your senses. These include:

Sight – observing a disease lesion (abscess, tumor).
Feel – palpating (feeling an abnormal lump in tissues, feeling abnormal firmness in an organ).
Smell – Smelling the urine odor of uremia, smelling the contents of a broken abscess).
Hearing – Listening to a carcass fall off the line on to the floor.

The Importance of Lymph Nodes

In order to detect diseases and contamination, you have to direct your attention to an area where they are likely to be observed. Diseases, abnormalities, and contamination can occur at any place on the carcass or its parts. However, diseases and abnormalities are mostly likely to produce visible or palpable lesions in specific locations. Of primary importance in organoleptic detection of disease is the lymphatic system. The lymphatics consist of vessels present throughout the tissues which drain into lymph nodes. Lymph nodes range in size from just visible to 3 to 4 inches across. Their appearance has been variously described as egg, cigar, or spherical shaped. All these shapes can be normal. The consistency (firmness) is between that of warm fat and muscle.
The color ranges from grey-brown to fat-colored. Some have light and dark markings. The normal range of appearances is wide, depending on the age of the animal, breed, species, and location in the body. The best way to learn what is normal is to look at all the lymph nodes. You can do this under the direction of your supervisor and/or experienced inspectors who will explain what you see.

Lymph nodes function as filters for disease microorganisms and abnormal or toxic chemicals in the tissue fluids of the body. An example you may have seen is blood poisoning in a hand or finger of a person. Red streaks that are not blood vessels become visible up the arm and a lump, with swelling and pain, develops in the armpit. The red streaks are inflamed lymph vessels. These are normally invisible to the eye. The lump is formed by the inflamed proper axillary lymph nodes. Under the skin you can see the redness and enlargement of the nodes. When diseased organisms or toxins begin to spread around the body, the lymph nodes are among the first tissues to become visibly affected. This is your signal that something is wrong.

The major lymph nodes are located in specific places and the fluids draining through them come from specific areas of the body. The lymph nodes and tissue responses found during the PHV's examination of retained carcasses will indicate the location and severity of the condition, and whether or not the disease has begun to spread around the animal's body. By evaluating these along with the ante mortem findings, plus laboratory results, if necessary, the PHV determines the acceptability of the carcass and parts for human food.

Some lymph nodes and tissues need to be incised so that the internal portions can be observed. The incision technique is critical. First, the cut edges must be smooth, not ragged or torn. Otherwise, the lesions of certain important diseases are difficult to detect. Lymph nodes should be sliced in thin parallel slices to expose the body of the node. Tuberculosis lesions, some abscesses, and other conditions are exposed by incision of lymph nodes. The wrist rolling motion that you will learn from your supervisor and experienced inspectors permits you to observe both sides of the slice. Here is a diagram showing the structure of a typical lymph node.

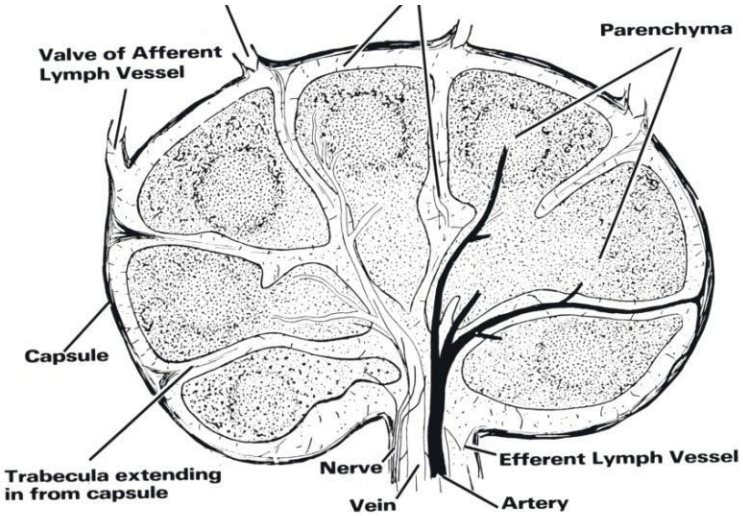

Figure 1
Diagram of a Typical Lymph Node

Livestock Anatomy

In order to perform inspection procedures appropriately, you must be familiar with the anatomy of a livestock carcass and its parts. For example, for swine postmortem, you will need to learn how to locate and identify the mandibular lymph nodes in the head; the mesenteric, hepatic, and tracheobrochial lymph nodes in the viscera; the lungs, heart, and the liver; and the kidneys of a carcass. (See Appendix for diagrams showing livestock anatomy.)

Postmortem Inspection Process

The postmortem inspection process for livestock involves the following steps:

Head inspection,
Viscera inspection,
Carcass inspection.

In large establishments, inspectors are assigned to cover one of these areas and rotate to different sites according to a rotation pattern. At small or very small establishments, the inspector may perform all of the postmortem inspection procedures on each animal. The inspection routines differ for each inspection site in each species. The differences reflect variations in anatomy, diseases, and method of dressing that the establishment uses.

In general, when abnormalities are observed while performing inspection, the following actions must take place:

1. If the disease or condition of the head, organ, or carcass is localized, have the establishment trim the affected tissues.

2. If the disease or condition is generalized and affects the majority of the head, organ, or carcass retain it for veterinary disposition.

The specific details for the inspection procedures for each of the livestock species covered by the regulations – cattle, sheep, swine, equine – differ. However, there are similarities. We will walk through the general steps involved in swine postmortem inspection and cattle as examples of postmortem inspection procedures. The postmortem inspection procedures for other species are shown in the Appendix of this module.

Presentation

The sequence of inspection will depend on the method of presentation for inspection that the establishment uses. But, regardless of the method, no part to be inspected may be missed, and the presentation must be consistent. This permits you to perform the same inspection sequence each time, and reduces the chances that a required inspection will be overlooked. A n example of
improper presentation is having the head missing. The head can't be inspected if it is missing. Remember, you must be able to determine at all times which parts belong to a carcass (e.g., 9 CFR 310.23). Therefore, the establishment must have a method of identifying the carcass and all its parts (e.g., tag).

Based on the severity and the frequency of the improper presentation, certain actions should be taken by inspection.

1. First, direct the designated establishment personnel to immediately remove the condition of improper presentation and delay inspection procedures until the condition is removed.

2. If action in #1 does not result in proper presentation, direct the designated establishment employee to stop the line and remove the condition if it cannot be removed prior to the carcass leaving the inspection area.

3. If conditions exist to the extent that the line has to be stopped repeatedly, delay inspection and ask establishment management to correct the problem.

4. The IIC may require the establishment to reduce the line speed until the conditions are favorable.

Online Inspection Duties for the Control of Feces, Ingesta, and Milk

As part of your online postmortem inspection duties you will verify removal of contamination (feces, ingesta, or milk) during the examination of carcasses and parts. FSIS enforces a zero tolerance standard for visible fecal, ingesta, or milk material on carcasses, head, cheek, and weasand meat at livestock slaughter establishments. The methods by which inspection personnel will verify zero tolerance standards are addressed in FSIS Directive 6420.2.

If you are performing <u>on-line head inspection</u> and find contamination, the establishment must remove the contamination before the head can be passed. If you repeatedly find contamination, you should notify off-line inspection program personnel. The off-line inspection program personnel will perform verification activities to determine whether the establishment's process and sanitary dressing procedures are controlling contamination during the head meat production process.

If you are performing <u>on-line carcass inspection</u> and find feces, ingesta, or milk, you would stop the slaughter line for carcass reexamination and rework unless the establishment has provided a rail-out loop to rail the contaminated carcass off-line for reexamination, trimming, and positioning back on the line for final inspection. You should notify off-line inspection personnel any time you believe that an establishment's rail-out procedure is inadequate to prevent carcass accumulation or cross-contamination of other carcasses, or an establishment's slaughter or dressing processes are not under control (for example, when repeated presentation of contaminated carcasses for postmortem inspection at the rail inspection station indicates failure of the establishment's sanitary dressing procedures to control contamination during the slaughter process).

If you are performing on-line inspection and find contamination on weasand meat during the harvesting step, the establishment must remove the contamination before the weasand meat can be passed. If you repeatedly find contamination, you should notify the off-line inspection program personnel. The off-line inspection program personnel will perform verification activities to determine whether the establishment's process and

sanitary dressing procedures are controlling contamination during the weasand meat production process.

Swine Inspection

Head Inspection Procedures

The head inspection procedures for swine are as follows:

1. Observe head and cut surfaces – the eyes, fat, cheek muscles, and other tissues for abnormalities.

2. Incise and observe the right and left mandibular lymph nodes.

3. When abnormal conditions are observed, retain the head for veterinary disposition.

Your supervisor and experienced inspectors will show you how to perform these procedures in detail.

Here are some common abnormal conditions observed during head inspection.

T*uberculosis* may be detected during head inspection in varying degrees. The inspector must condemn the head if any amount of tuberculosis is found in the head during head inspection. The head is usually stamped at the viscera inspection station and the nodes in the jowls removed and condemned as required. Ensure that the carcass is also identified with a retain tag (9 CFR 311.2).

Abscesses are another common finding during the inspection of the head. When slight, small, well-encapsulated abscesses are found on head inspection, the carcass should be tagged. When well-marked or extensive abscesses are seen, the carcass should also be tagged by the head inspector. Ultimately, the disposition of the extensive or well-marked abscessed head will be condemnation (probably at the viscera inspection station) and the disposition of a head with a slight, small, well encapsulated abscess will be passed after the affected areas in the jowl, the mandibular lymph node, and adjacent lymph nodes are removed and condemned (9 CFR 311.14).

At the head inspection station you may see *atrophic rhinitis*. Swine with atrophic rhinitis may have a characteristic nose disfiguration, absence of nasal turbinate bones, and small amounts of pus or exudate in the nasal sinuses. The turbinate soft tissues may be present, but they are folded against the nasal cavity wall since the supporting bony structure has disappeared. Since this condition is usually localized, head tissues can be removed without contamination and saved for food.

Some other conditions you may observe include *icterus, arthritis, erysipelas*, and *septicemic skin lesions*. We will discuss these conditions in the carcass inspection section of this module.

If the head contains abnormal or diseased conditions, then the carcass and its parts as well as the head are tagged with retain tags by the inspector indicating that they are to be railed out to the carcass disposition area for examination by the veterinarian.

In addition to observing abnormal conditions in heads, postmortem inspectors also identify improper presentation by the establishment. Here are some examples of improper presentation of swine for inspection:

Head missing--the head can't be inspected if it is missing. Remember, you must be able to determine at all times which parts belong to a carcass (310.23). Therefore, the establishment must have a method of identifying the carcass and all its parts (e.g., tag).

Mandibular lymph nodes left in the neck instead of on the head.

Hair or surface contaminants such as dirt on the head.

Swine Viscera Inspection

Viscera include the contents (organs) of the animal's abdominal and thoracic cavities. You must be able to determine at all times which parts belong to a carcass. Therefore, the establishment must have a method of identifying the carcass and all its parts (e.g., tag).

Viscera inspection includes the following steps:

1. Observe the eviscerated carcass, viscera, and parietal (top) surface of spleen.
2. Observe and palpate mesenteric lymph nodes.
3. Palpate portal lymph nodes.
4. Observe dorsal (curved) surface of lungs.
5. Palpate bronchial lymph nodes – right and left.
6. Observe mediastinal lymph nodes.
7. Turn lungs over and observe ventral (flat) surfaces.
8. Observe heart.
9. Observe dorsal (curved) surface of liver.
10. Turn the liver over and observe ventral (flat) surface.

You will also observe non-gravid uteri and ovaries when they are saved for edible purposes.

Your supervisor and experienced inspectors will show you how to perform these procedures in detail.

When abnormal conditions are observed that could affect carcass disposition, retain the viscera and carcass for veterinary review.

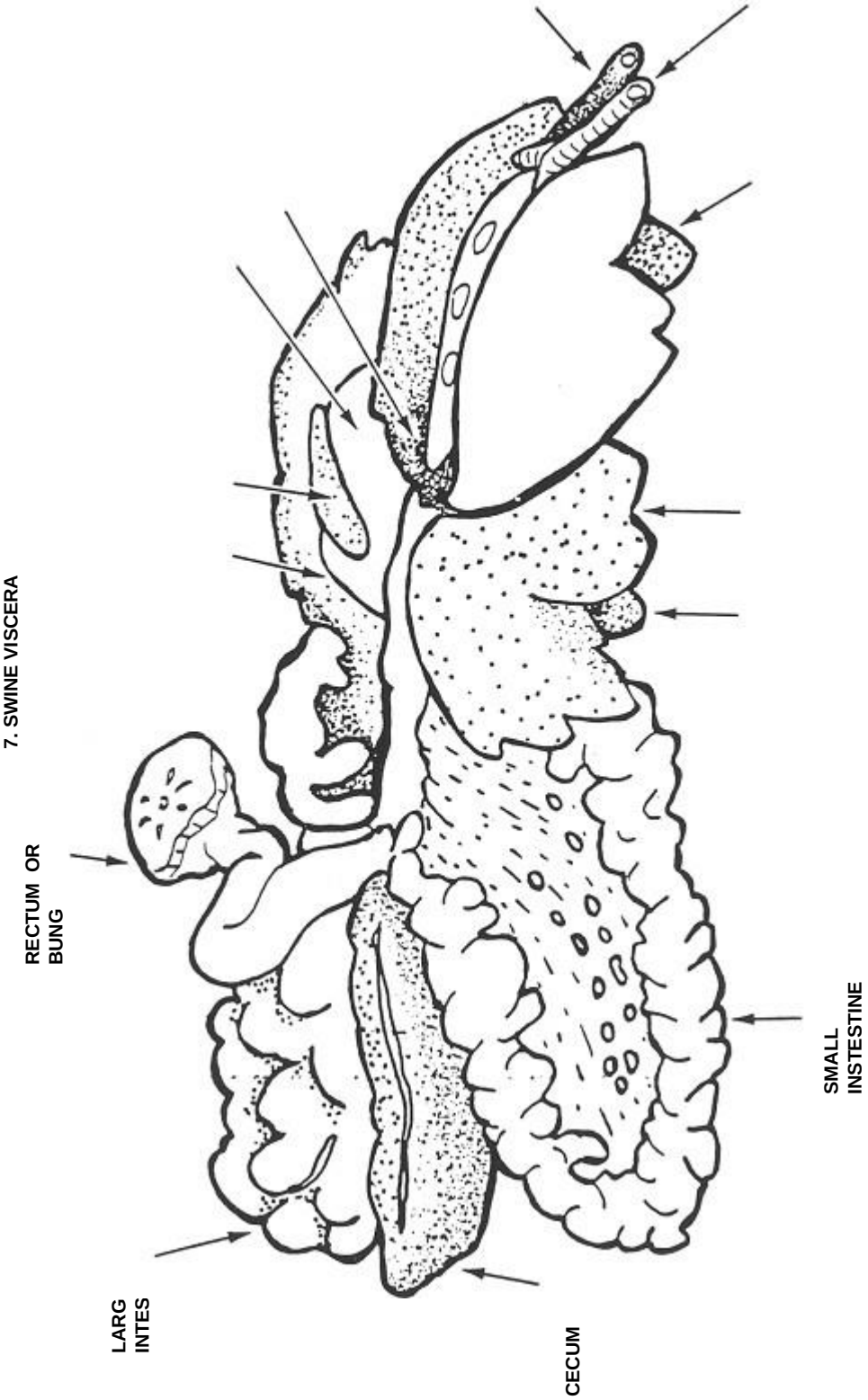
7. SWINE VISCERA
RECTUM OR
BUNG
LARG
INTES
CECUM
SMALL
INSTESTINE

Here are common abnormal conditions that are observed during viscera inspection.

Arthritis--joints with localized arthritis and corresponding lymph nodes shall be removed and condemned during dressing operations and before inspection is completed. (9 CFR 311.7)

Malignant Lymphoma—neoplasia of the lymph tissue. Tumors can be found anywhere in the viscera or carcass. Retain for veterinary disposition. (9 CFR 311.11(b))

Melanoma--these are tumors that contain black pigment (melanin). Retain these for veterinary disposition. (9 CFR 311.11(a))

Melanosis – this condition is created by the abnormal deposition of the melanin pigment in various tissues. It is most commonly found in the lungs and liver. You would have all affected tissues removed and condemned. If you believe it is generalized, retain for veterinary disposition.

Pleuritis/peritonitis--localized, chronic inflammatory processes with adhesions may be "peeled out" with the remainder of the carcass passed for food. If acute, extensive, or other associated pathology is present, the carcass and its parts should be retained for veterinary examination. (9 CFR 311.16(a) (1))

Pneumonia—lungs will have varying degrees of inflamed tissue which will usually have a red or purple coloration and will feel heavy or fluid-filled. If acute, extensive, or other associated pathology is present, the carcass and its parts should be retained for veterinary examination. (9 CFR 311.16(a) (1))

Enteritis—intestinal tract is hemorrhagic in appearance. If extensive, or acute, retain the carcass and parts for veterinary examination. (9 CFR 311.16(a) (3))

Nephritis--one or both kidneys may be affected. Localized conditions require the affected kidney(s) to be removed and condemned. If there is doubt as to whether the condition is localized to the kidney or if other pathology exists, the carcass should be retained. (9 CFR 311.16(a) (7))

Embryonal nephroma--these are tumors of the kidney. Generally, they are benign and occur more commonly in young animals. These should be retained for veterinary disposition. (9 CFR 311.11(a))

Hydronephrosis--one of both kidneys literally become a "bag of water". Normal kidney tissue is replaced by fluid. There is generally no effect upon the carcass. Affected kidneys are removed and condemned. (9 CFR 311.16(a) (7))

Sexual odor--each boar hog that is slaughtered should be screened for the pungent sexual odor that is characteristic in some boar hogs. If sexual odor is detected by the viscera inspector, the carcass and viscera should be retained for veterinary disposition. (9 CFR 311.20)

Pericarditis--if acute, extensive, or other pathology is detected, retain for veterinary disposition. If pericarditis is localized and chronic (adhesions of the pericardial sac to the wall of the heart), the heart and pericardium is condemned, but the carcass may be passed for food. (9 CFR 311.16(a))

Cysticercosis (pork measles)--a parasitic condition caused by a tapeworm cyst (*Taenia solium cysticercus*). Similar to beef measles, it can affect any muscle tissue

in the carcass. In pork, the heart seems to be the most common site. The carcass and parts must be retained for the veterinarian to examine. (9 CFR 311.24)

Icterus--the carcass has a lemon-yellow appearance. Icterus particularly affects connective tissues (tendons, ligaments, sclera of the eye, etc.). Carcasses affected with any degree of icterus are retained for veterinary disposition. (9 CFR 311.19)

Hog cholera--identified by such findings as hemorrhagic lymph nodes and red spots on belly and legs, and possibly a "turkey egg" kidney. If abnormal hemorrhages are observed, the carcass should be retained for veterinary disposition. (9 CFR 311.3)

Septicemia--a generalized inflammatory condition caused by pathogenic bacteria and associated toxins in the blood. Most, or all, of the body lymph nodes may be enlarged, hemorrhagic, and edematous. Kidneys may have petechiae (small pinpoint hemorrhages). Other pathology may be present. Retain the carcass for veterinary disposition. (9 CFR 311.16(a) (2))

Ascarids--the larva of these roundworms frequently migrate through the liver and cause scarring on the livers surface. "Slight" scarring may be trimmed (spotting the liver). More than slight evidence of ascarids requires the liver to be condemned. (9 CFR 311.25(a))

Abscesses--If the carcass has been tagged by the head inspector for a slight cervical abscess and the viscera inspector finds tuberculosis (TB) in the viscera, the carcass and viscera must be retained for veterinary disposition. If no lesions are found in the viscera, the viscera inspector will permit the head to be used for food after complete removal and condemnation of the mandibular and adjacent lymph nodes in the jowls. However, if the establishment does not choose to trim as described, the head and jowls will be condemned. (9 CFR 311.14)

Tuberculosis (TB)--the primary seats of TB are defined as the mandibular, the mesenteric, and the mediastinal lymph nodes in swine. These sites are regarded as the primary seats for disposition purposes only and do not necessarily have any correlation with the frequency at which tuberculosis is found in any location. Probably the most common sites at which tuberculosis lesions would be found would be the mandibular and mesenteric nodes and the liver. The food inspector is authorized to make a limited disposition for tuberculosis on a swine carcass with TB lesions in only one primary seat. For example, if tuberculosis is found in the mesenteric lymph nodes only, it is not necessary to tag the carcass and retain it. However, if there is TB in more than one primary seat or in any site other than a primary seat, then that carcass and viscera must be retained for veterinary disposition. (9 CFR 311.2)

Suffocated (Asphyxia) - a scarlet red appearance of the organs that are engorged with blood; must be retained for veterinary disposition. (9 CFR 311.30)

Overscald – carcasses that have been overscalded will have a cooked appearance and will usually have varying degrees of mutilation and contamination of tissues with scald vat water. Retain for veterinary disposition. (9 CFR 310.18(a))

As in head inspection, there are various forms of improper presentation that occur at the viscera inspection station. Contamination with feces or ingesta is one of the most common defects. Hair, toenails, pus, bile, and parts of viscera missing are other common examples of improper presentation. When improper presentation occurs, take the same actions as was discussed previously in this module.

Swine Carcass Inspection

There are four steps to carcass inspection.

1. Observe the back of the carcass. This may involve observing it in a mirror, or turning the carcass manually.

2. Observe the front parts and the inside of the carcass.

    a. Observe all cut surfaces.
    b. Observe all body cavities (pelvic, abdominal, and thoracic).
    c. Observe the lumbar region.
    d. Observe the neck region.

3. Grasp, turn, and observe the kidneys (both sides).

Your supervisor and experienced inspectors will show you how to perform these procedures in detail.

If abnormal conditions seen on carcass inspection do not require veterinary disposition, the inspector can have the establishment employee properly trim the carcass. However, some abnormal conditions require retention for veterinary disposition.

6. SWINE CARCASS - INSIDE

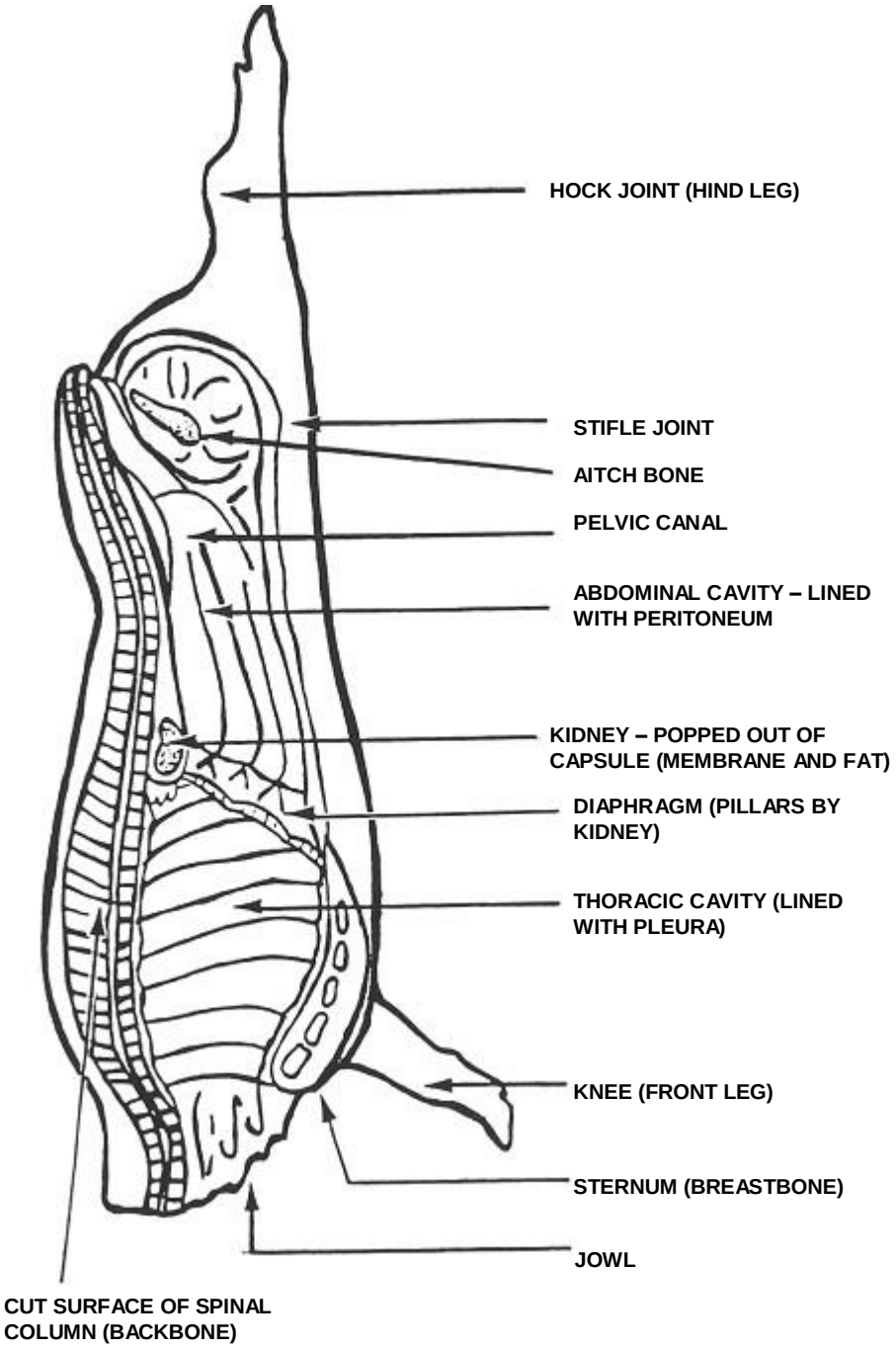

SWINE VISCERA INSPECTION ROUTINE SEQUENCE

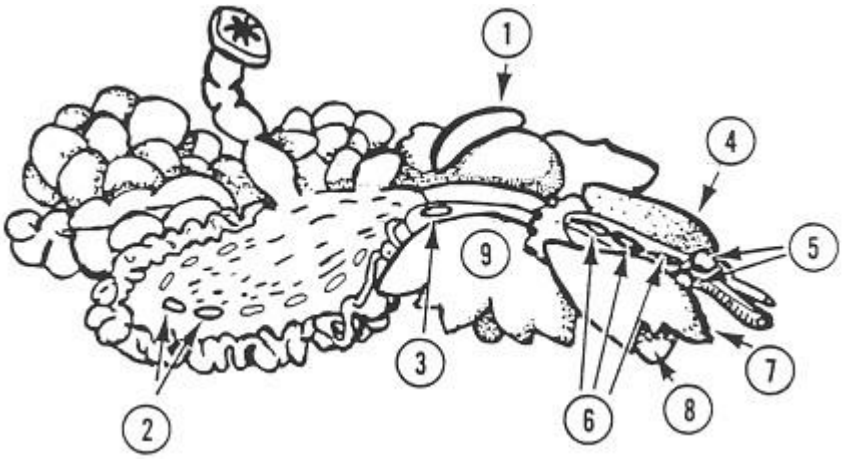

KEY:

1. SPLEEN
2. MESENTERIC LYMPH NODES
3. PORTAL LYMPH NODES
4. DORSAL SURFACE OF LUNGS
5. TRACHEOBRONCHIAL (BRONCHIAL) LYMPH NODES
6. MEDIASTINAL LYMPH NODES
7. VENTRAL SURFACE OF LUNGS
8. HEART
9. LIVER

Here are some examples of abnormal conditions that may be seen during carcass inspection.

Arthritis--arthritis in a joint may be indicated by the appearance of the lymph nodes associated with that joint. For example, enlarged, darkened internal iliac lymph nodes are a common finding with arthritis in the hindquarters. (9 CFR 311.7)

Abscesses--abscesses may be found anywhere in the carcass or its parts. (9 CFR 311.14)

Diamond skin disease--these carcasses should be retained for veterinary disposition. While most are trimmed and passed for food, the veterinarian may find systemic involvement and condemn the carcass. (9 CFR 311.6)

Nephritis one or both kidneys may be affected. Localized conditions require the affected kidney(s) to be removed and condemned. If there is doubt as to whether the condition is localized to the kidney or if other pathology exists, the carcass should be retained. (9 CFR 311.16(a)(7))

Pleuritis/peritonitis--localized, chronic inflammatory processes with adhesions may be "peeled out" with the remainder of the carcass passed for food. If acute,

extensive, or other associated pathology is present, the carcass and its parts should be retained for veterinary examination. (9 CFR 311.16(a)(1))

Cysticercosis--cysticercosis (measles), or cysts, can be found in any muscle tissue. Retain for veterinary disposition. (9 CFR 311.24)

Melanoma--these are tumors that contain black pigment (melanin). Retain these for veterinary disposition. (9 CFR 311.11(a))

Neoplasia (malignant lymphoma)--these tumors are commonly found in and around lymph nodes, but may be detected anywhere. They are always considered malignant and must be retained for the veterinarian. Anytime you detect an abnormal mass (tumor), you should retain the carcass for veterinary disposition. (9 CFR 311.11)

Cystic kidney--clear, fluid filled cysts of varying sizes. Condemn the kidneys (unless the condition is slight) and pass the carcass for food. (9 CFR 311.16(a)(7))

Embryonal nephroma--retain for veterinary disposition. (9 CFR 311.11(a))

Kidney worms--this condition, caused by parasites, can also be seen in the soft tissue of the carcass and abdominal viscera. Generally this is a localized condition. Condemn the kidney and affected tissues. (9 CFR 311.25)

Adhesions--these fibrous bands form as a chronic response to inflammation and are an attempt by the body to heal. They cause parts/organs to be joined abnormally. Condemn affected parts and pass the carcass if no other pathology is noted.

Abscess in the backbone--always check carefully along the backbone of the split carcass. It is possible to see abscesses, neoplasms (tumors), or evidence of trauma (fractures and bruising). (9 CFR 311.14)

Bruises--bruised tissue should be trimmed and condemned. If evidence of infection exists, retain the carcass for veterinary disposition. (9 CFR 311.14)

Carcasses tagged for cervical tuberculosis – if only found in the cervical area the carcass would be passed after condemnation of the head and removal of affected cervical tissues. (9 CFR 311.2(e))

Carcasses tagged for slight cervical abscess, or well-marked or extensive cervical abscess – pass the carcass after removal of affected tissues which may include condemnation of the head. (9 CFR 311.14)

Once again, if improper presentation occurs, take the same actions as when it occurs at head or viscera inspection.

Swine Inspection Workshop

1. Select from the following those items that would be considered examples of improper presentation inspection or examples of carcass abnormalities. Use code "IP" for selecting improper presentation examples and "A" for abnormalities.

   _____ a. Head missing

   _____ b. Toenails or hoofs present

   _____ c. Arthritis

   _____ d. Icterus

   _____ e. Mandibular nodes in the neck

2. Select the proper ultimate disposition of swine heads affected with tuberculosis or various degrees of abscessation. Use the following codes to mark your dispositions:

   C = Condemn head and adjacent nodes in jowls

   T = Have affected areas trimmed and allow the head to be passed for human food.

   _____ a. Head with very slight tuberculosis lesions in one mandibular lymph node.

   _____ b. Head with extensive tuberculosis of the mandibular lymph nodes.

   _____ c. Head with slight abscess of the tissues.

   _____ d. Head with extensive, draining-type abscess.

3. If you were the assigned inspector on a hog kill slaughtering 75 hogs per hour and after about 1 hour of work a hog came down the line with two machine cuts not trimmed, what would be your best course of action for this improper presentation? This is the first instance of improper presentation today. (Mark you choice with an X.)

   _____ a. Stop the slaughtering chain, leave your position, seek out the establishment manager to discuss the improper presentation.

   _____ b. Direct the properly designated establishment personnel to immediately remove the condition of improper presentation and delay inspection procedures until the condition is removed.

4. Answer the following questions about lesions, general finding, or appearance of the following conditions:

A. Icterus

(1) appearance of carcass -

(2) Inspector action -

B. Arthritis

(1) Inspector action –

C. Pericarditis

(1) Site of infection -

(2) Inspection action -

D. Cysticercosis

(1) Usual site of infection –

(2) Appearance –

E. Overscald

(1) Appearance –

F. Cystic kidneys

(1) Appearance –

Cattle Inspection

The basics of the cattle postmortem inspection process are similar and follow the same principles of livestock inspection. You must be familiar with cattle anatomy. You must also use lymph nodes as an indicator of diseases and conditions that are unwholesome. Cattle inspection involves the following steps:

Head inspection,
Viscera inspection,
Carcass inspection.

No step in the inspection process may be omitted.

In general, when abnormalities are observed while performing inspection, the following actions must take place:

1. If the disease or condition of the head, organ, or carcass is localized, have the establishment trim the affected tissues.

2. If the disease or condition is generalized and affects the majority of the head, organ, or carcass retain it for veterinary disposition.

You must also ensure that the establishment presents cattle heads, viscera, and carcasses properly. Once again, the sequence of inspection will depend on the method of presentation for inspection that the establishment uses. But, regardless of the method of presentation, no part to be inspected may be missed, and the presentation must be consistent from animal to animal. This permits you to perform the same inspection sequence each time, and reduces the chances that a required inspection will be overlooked. One example of improper presentation is having the head missing. The head can't be inspected if it is missing. Remember, you must be able to determine at all times which parts belong to a carcass (e.g., 9 CFR 310.23). Therefore, the establishment must have a method of identifying the carcass and all its parts (e.g., tag).

Again, based on the severity and the frequency of the improper presentation, certain actions should be taken by inspection.

1. First, direct the designated establishment personnel to immediately remove the condition of improper presentation and delay inspection procedures until the condition is removed.

2. If action in #1 does not result in proper presentation, direct the designated establishment employee to stop the line and remove the condition if it cannot be removed prior to the carcass leaving the inspection area.

3. If conditions exist to the extent that the line has to be stopped repeatedly, delay inspection and ask establishment management to correct the problem.

4. The IIC may require the establishment to reduce the line speed until the conditions are favorable.

Online Verification Duties for Control of Specified Risk Materials (SRMs)

FSIS issued three regulations and a notice in the Federal Register on January 12, 2004, in response to the diagnosis by USDA of a positive case of BSE in an adult cow in the State of Washington. These regulations and the notice were designed to minimize human exposure to materials that scientific studies have demonstrated as containing the BSE agent in cattle infected with the disease. The guidance from multiple FSIS Notices has been incorporated into FSIS Directive 6100.4, Verification Instructions Related to Specified Risk Materials (9/13/2007). The regulations prohibit the slaughter of non-ambulatory disabled cattle and identify a list of Specified Risk Materials
(SRMs) that may present a risk for transmitting Bovine Spongiform Encephalopathy (BSE) and are now inedible:

For all cattle:

The tonsils are a SRM
The distal ileum is a SRM

For cattle 30 months of age and older:

The skull, eyes, brain, and trigeminal ganglia are the SRMs
The vertebral column (except the transverse processes of the thoracic and lumbar vertebrate and the wings of the sacrum), spinal cord and dorsal root ganglia (DRG) are the SRMs

When you are performing your online inspection duties and observe visible (readily identifiable) specified risk materials (SRMs) on edible portions of the product, the establishment may recondition the entire carcass or head by knife trimming. You are to notify the PHV or, if unavailable, other off-line inspection program personnel when there is evidence that an establishment's SRM control program is ineffective (for example, when repeated presentation of contaminated heads or carcasses for post-mortem inspection at the rail and head inspection station indicates failure to control SRM contamination). The PHV or other off-line personnel will perform the appropriate HACCP or Sanitation SOP procedures to evaluate the process.

Head Inspection

The sequence of inspection of the head tissues, lymph nodes, cheek muscles, and tongue is determined by the direction of movement of the heads and whether the tongue is in front of the head or behind it. Usually, the leading tissues are examined first, and the trailing tissues are examined last. In the establishment, your supervisor and the other inspectors will show you the sequence of inspection. The presentation methods used by establishments can vary. For example, some establishments present the heads with the tongue in and others present the head with the tongue out. Regardless of the presentation method used by the establishment, certain tissues are always examined, although the sequence, or order, may vary. Also, remember that any and all parts separated from the carcass must be kept positively identified as belonging to a specific carcass until after all phases (head, carcass, viscera) of inspection have been completed. The positive identification of all separated parts is necessary in case the carcass and its parts need to be retained for examination by the veterinarian. Following are the general steps you will perform.

There are four steps in head inspection.

Step one: observe the outer surface of the head and eyes.

Step two: incise and observe the four pairs of lymph nodes – mandibular, parotid, lateral retropharyngeal, and medial retropharyngeal.

Step three: incise and observe the masticatory or cheek muscles.

Step four: observe and palpate the tongue.

Conditions which you may see during head inspection include the following.

Contamination may be observed the in form of pieces of hide, hair, ear tubes, ingesta, rust, and grease. When these or any other contaminants are present on the head when it is presented for inspection, you will delay inspection until the condition is removed by a company employee. (9 CFR 310.18(a))

Abscesses are a common finding in soft tissues of the head, particularly the lymph nodes. The abscesses are generally localized, but you should retain the head and carcass until completion of all inspection. (9 CFR 311.14)

Actinomycosis (acti) (lumpy jaw) is generally located in the bony structures of the head and jaws. It may be abscessed and is usually characterized by swelling. When the condition is localized, the head is usually condemned and the corresponding carcass will be retained, pending further inspection. (9 CFR 311.9)

Actinobacillosis (acti) (wooden tongue) is generally located in the soft tissue of the head, such as the tongue and/or lymph nodes. The condition is frequently mistaken for an abscess and, if localized, part of the head may be salvaged after the removal of affected tissue. In some cases, this condition may be found in the viscera and lungs of the animal so the carcass is retained until after all inspection has been completed. (9 CFR 311.9)

Epithelioma (cancer eye) (bug eye) is the most common neoplasm of cattle. All breeds are susceptible, but Herefords are by far the most commonly affected. It is felt the tumor originates in either the cornea, third eyelid, or the eyelids, and usually progresses to the surrounding bone and adjacent region. The obvious lesions will have been detected on antemortem inspection, and the animals will be handled as suspects. The lesion may appear as a small growth on the cornea or eyelid or there may be no lesion at all. In some cases the eye may be missing after having been surgically removed prior to slaughter. You would retain all heads and their corresponding carcasses when they exhibit any of these signs. (9 CFR 311.12)

Tuberculosis - One of the primary reasons you incise lymph nodes is to detect TB. The affected lymph node involvement will vary from slightly involved to totally involved. When incised, the node affected usually exhibits a yellowish semi-liquid to caseous (cheese-like) mass of tissue interspersed with some normal tissue, greyish in color, and often showing signs of inflammation. When you detect what you suspect is TB, you must retain the head and corresponding carcass. (9 CFR 311.2)

Cysticercosis is a parasitic condition in which larval cysts of the beef tapeworm *Taenia saginata* are found in the muscle tissue. The cyst is found chiefly in the muscles of the jaw, heart, and diaphragm. However, it may be found in other muscle tissue as well. A live cyst has the appearance of a pearl or fluid-filled sac. The cysticerci may die shortly after development and the lesion may calcify. A calcified lesion (dead cyst) is usually yellowish in color and when incised by the knife will sometimes give you the feeling that you have cut through some granular (gritty) material. Since the bovine animal is only the intermediate host for this parasite, while the human is the definitive host, you must always retain the head and carcass when a cyst is found, dead or alive. The veterinarian will perform a special expanded inspection procedure to determine the ultimate disposition of the carcass. (9 CFR 311.23)

Eosinophilic Myositis (EM) lesions are most frequently detected (by observation) in the muscles of the cheeks, in the tongue, in the heart, and in the esophagus. They may invade other skeletal muscle tissue as well. The most common lesions are small, irregularly distributed, yellowish-green, yellowish, or greyish-white pin-head shaped spots. They may also appear as larger bright green to greenish-grey areas that vary in size from that of a dime to the size of the palm of the hand. Since the condition may also be found in other sections of the carcass, you should retain the head and carcass for a final disposition by the veterinarian. (9 CFR 311.35)

Bruised Tissue - depending on the degree of bruised tissue, you will determine if the head should be condemned or trimmed by a company employee. You would not normally retain the carcass because of bruised tissue on the head. (9 CFR 311.14)

Steatosis - this muscular condition principally affects cattle in feedlots and is characterized by a replacement of the muscle fibers by fat tissue. There is not inflammation involved. It usually occurs in the heavier muscles of the back and shoulders. It is seen frequently enough at the head inspection station to be mentioned, however. The condition does not affect the carcass in any other way, so after removal of the affected area, the carcass is passed for food. (9 CFR 311.35)

Xanthosis (Brown atrophy of the musculature) - this brownish discoloration of the skeletal and heart muscles is the result of excessive quantities of waste pigment being deposited in the muscles. Xanthosis is usually found in older cattle and those cattle suffering from chronic wasting disease. The masseter (cheek) muscle, tongue, and heart are most often affected. When there is extensive discoloration of the musculature of the carcass, it is unfit for food. When the condition is slight and localized, the carcass is passed for food after the localized condition has been removed by trimming. If you have any doubt about how extensive the condition is, you should retain the head and carcass for the veterinarian's disposition. (9 CFR 311.13)

Cactus Thorns - cattle tongues with palpable foreign bodies and/or foreign body abscesses shall be condemned. (9 CFR 311.14)

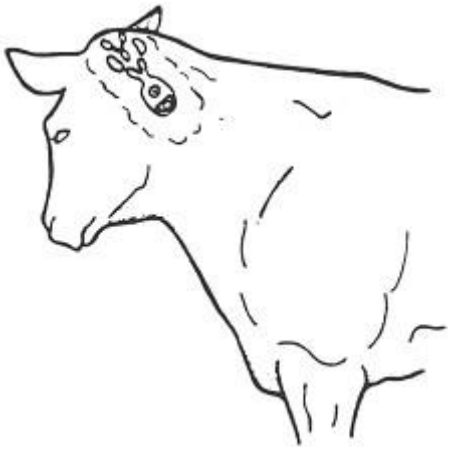

FOUR LANDMARKS

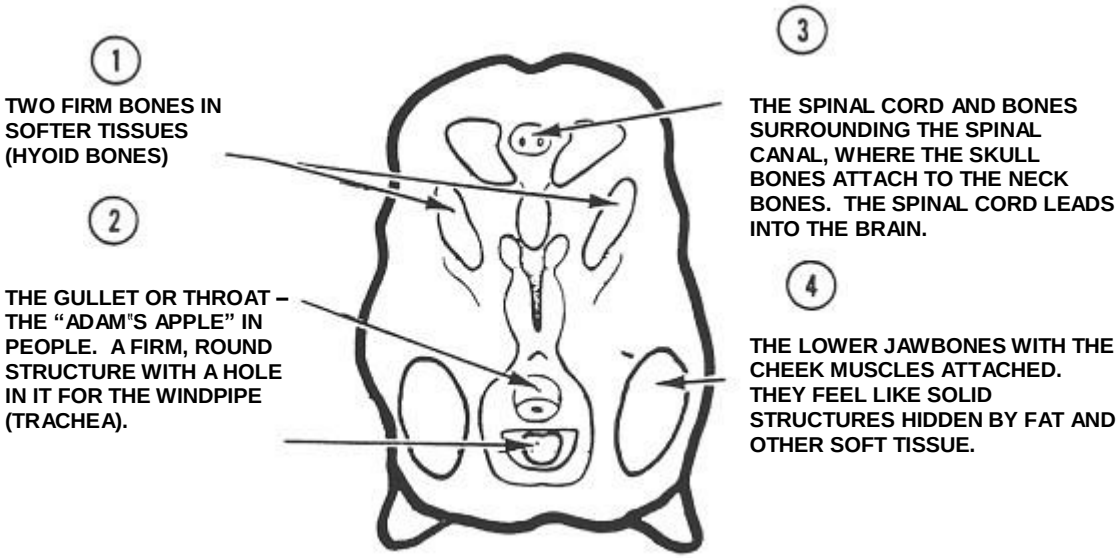

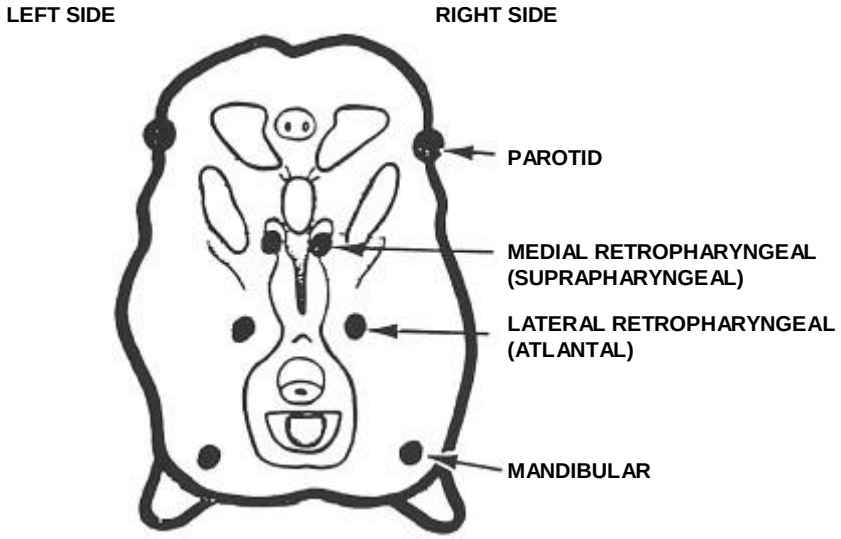
LEFT SIDE
RIGHT SIDE
PAROTID
MEDIAL RETROPHARYNGEAL
(SUPRAPHARYNGEAL)
LATERAL RETROPHARYNGEAL
(ATLANTAL)
MANDIBULAR

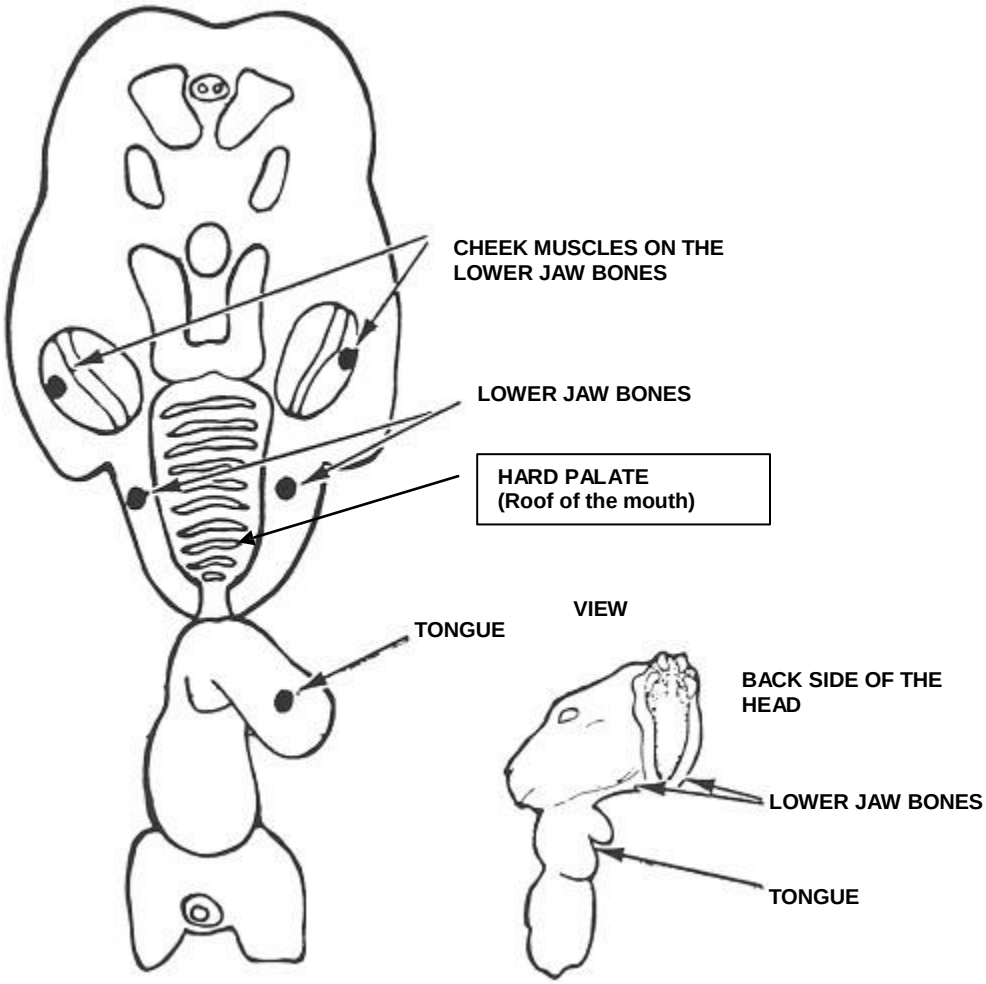
CHEEK MUSCLES ON THE
LOWER JAW BONES
LOWER JAW BONES
HARD PALATE
(Roof of the mouth)
TONGUE
VIEW
BACK SIDE OF THE
HEAD
LOWER JAW BONES
TONGUE

Examples of improper presentation that you may observe while performing head inspection include the presence of horns, hide, eyelids, hair, dirt, etc.

Viscera Inspection

Remember that the viscera include the contents of the abdominal and thoracic cavities plus the tubes that lead into and out of some of the organs in these cavities. Viscera separation is the dividing of the internal organs of the body such as the heart, lungs, liver, kidneys, intestines, etc., into various offal products. Offal parts are animal parts other than the carcass (body). Viscera are typically presented for inspection in a viscera truck or on a moving table. Regardless of the method used by the establishment to present the viscera, certain tissues are always examined.

The following steps are performed in viscera inspection.

1. Observe cranial and caudal mesenteric (mesenteric) lymph nodes, and abdominal viscera.
2. Observe and palpate rumeno-reticular junction.
3. Observe esophagus and spleen.
4. Incise and observe lungs lymph nodes - mediastinal [caudal (posterior), middle, cranial (anterior)], and tracheobronchial (bronchial) right and left.
5. Observe and palpate costal (curved) surfaces of lungs.
6. Incise heart, from base to apex or vice versa, through the interventricular septum, and observe cut and inner surfaces.
7. Turn lungs over; observe ventral (flat) surfaces and heart's outer surface.
8. Incise and observe hepatic (portal) lymph nodes.
9. Open the bile duct (both directions) and observe its contents for flukes.
10. Observe and palpate liver's ventral surface.
11. Turn liver over, palpate renal impression, observe and palpate parietal (dorsal) surface.

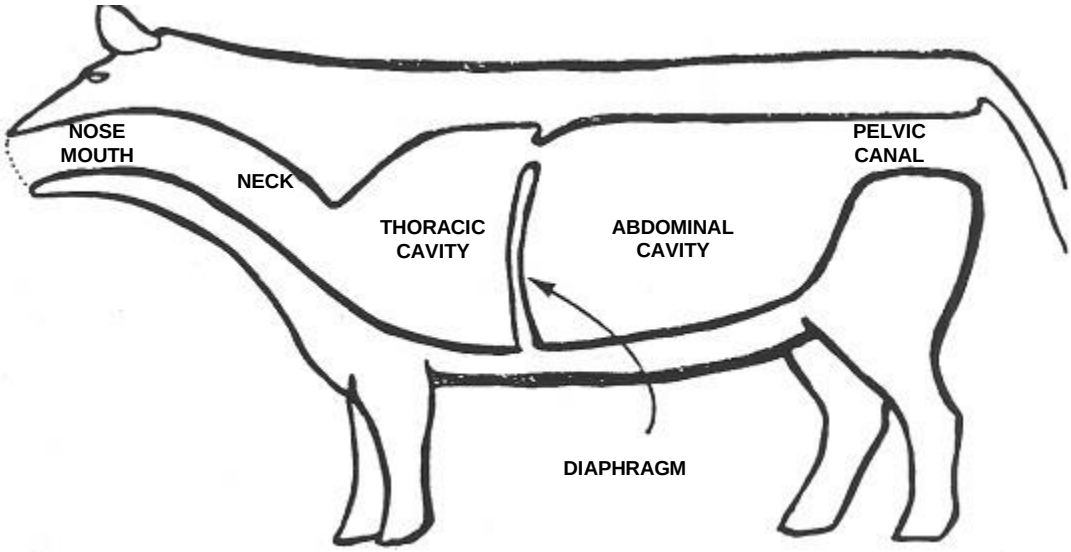
NOSE
MOUTH
NECK
THORACIC
CAVITY
ABDOMINAL
CAVITY
PELVIC
CANAL
DIAPHRAGM

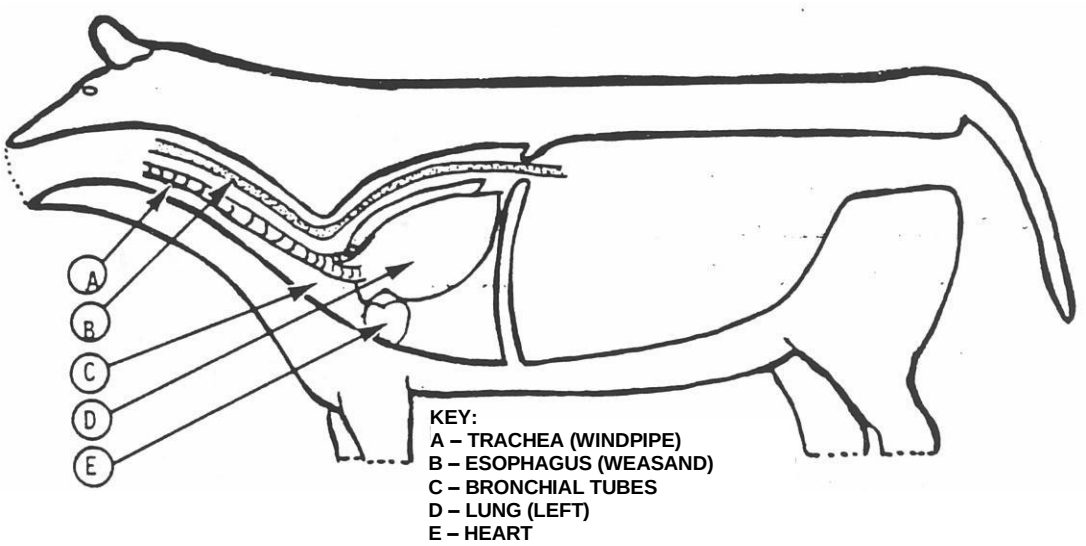
A
B
C
D
E
KEY:
A – TRACHEA (WINDPIPE)
B – ESOPHAGUS (WEASAND)
C – BRONCHIAL TUBES
D – LUNG (LEFT)
E – HEART

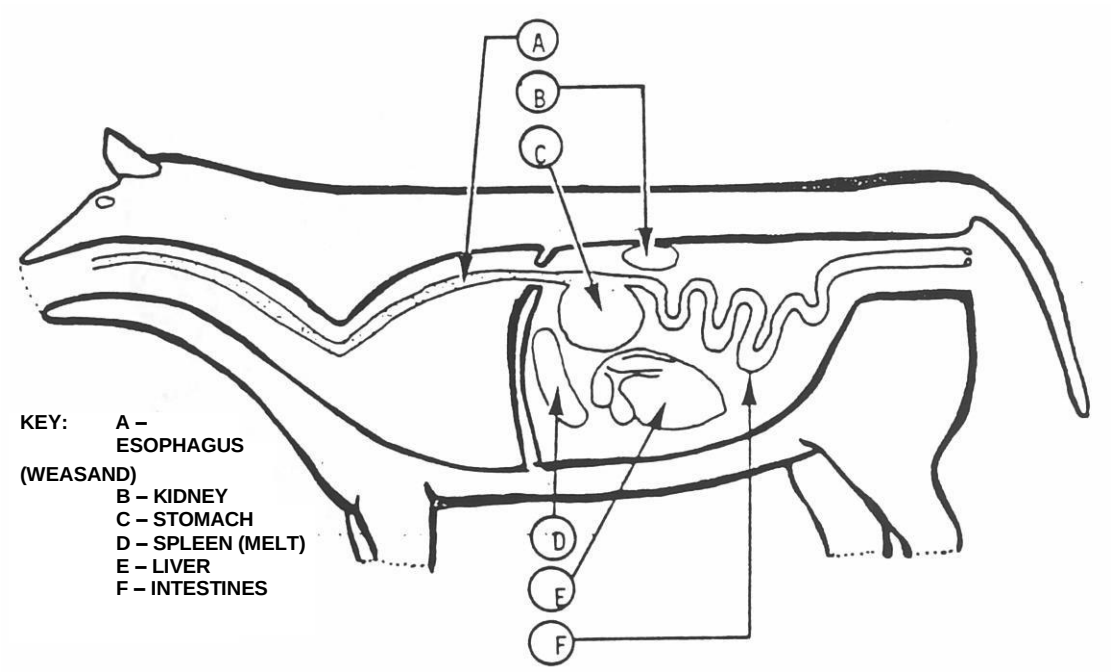
A
B
C
D
E
F
KEY: A – ESOPHAGUS (WEASAND)
B – KIDNEY
C – STOMACH
D – SPLEEN (MELT)
E – LIVER
F – INTESTINES

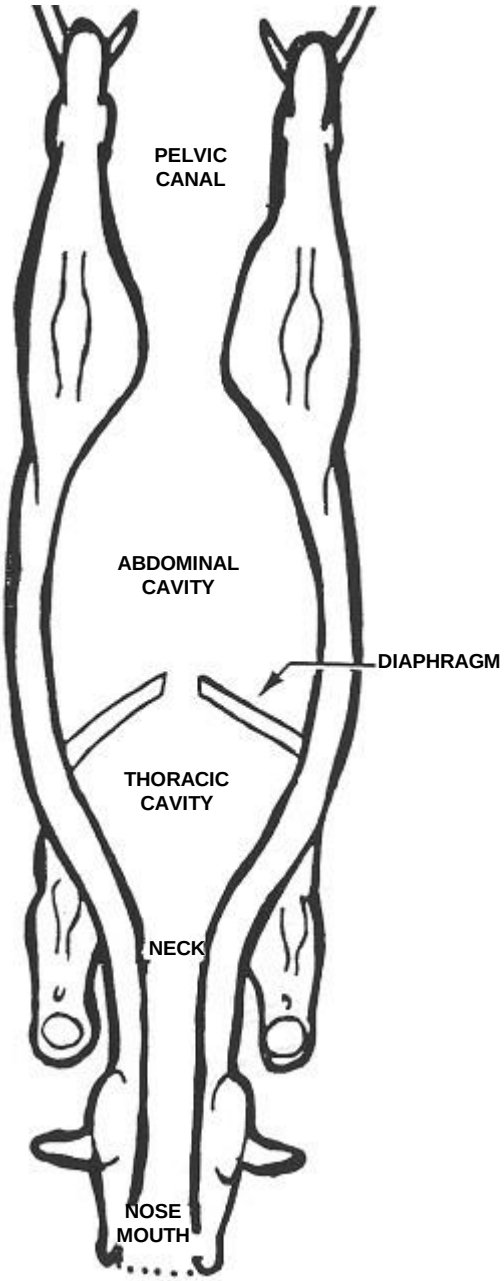
PELVIC
CANAL
ABDOMINAL
CAVITY
DIAPHRAGM
THORACIC
CAVITY
NECK
NOSE
MOUTH

THE THORACIC VISCERA

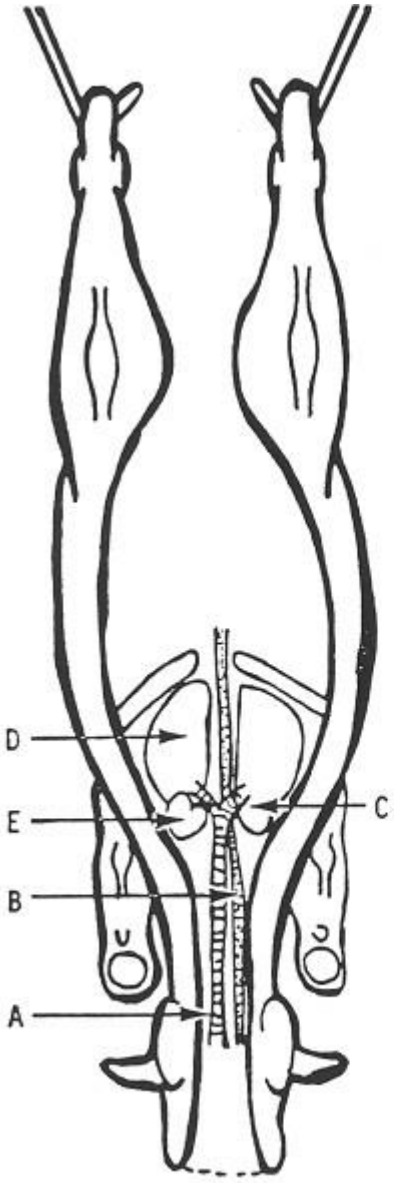

KEY

A – TRACHEA (WINDPIPE)
B – ESOPHAGUS (WEASAND)
C – BRONCHIAL TUBES
D – LUNG (LEFT)
E – HEART

THE ABDOMINAL VISCERA

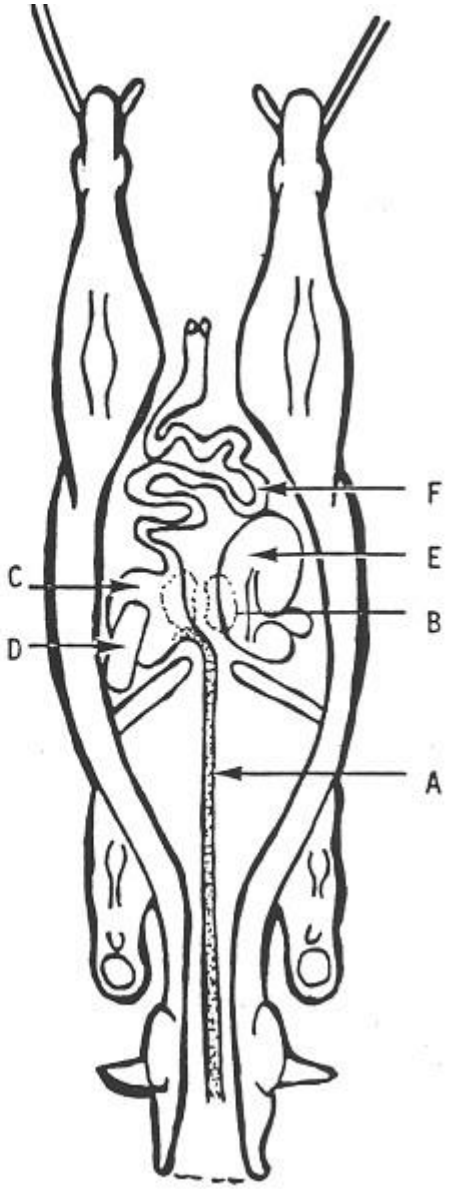

KEY

A – ESOPHAGUS (WEASAND)
B – KIDNEY
C – STOMACH
D – SPLEEN (MELT)
E – LIVER
F – INTESTINES

Conditions Observed at Viscera Inspection

There are many possible conditions that may be observed at viscera inspection. The liver and kidneys have certain conditions that are specific to these organs so we will discuss them separately. For the other visceral organs, here are the most commonly seen conditions.

Abscesses are frequently detected, especially in the palpation and observation of the rumeno-reticular junction. These abscesses are usually localized and require only that the viscera be condemned; however, you should be alert to the overall condition of the carcass and thoracic viscera. If abscesses are also found in other locations it could be an indication of a generalized condition in which case you would retain the carcass and all parts for the veterinarian. (9 CFR 311.14)

Tuberculosis may also be detected during viscera inspection especially in the incision of the lung's lymph nodes. When TB lesions are detected, the carcass and all parts must be retained. (9 CFR 311.2)

Granuloma - A granuloma may be detected especially in the thorax. It will usually appear as a variably sized solid to semi-solid lesion that is of caseous, or cheese-like, consistency. Retain the viscera and carcass for veterinary disposition. (9 CFR 311.36)

Neoplasms (tumors) may be detected during viscera inspection. These tumors typically would appear as nodules or lumps in or on visceral parts. Many of these neoplasms have the capability of spreading to other parts of the carcass and parts. Whenever you see a neoplasm, the carcass and all parts would be retained for veterinary disposition. Some of the most common neoplasms include the following. (9 CFR 311.11)

> *Malignant lymphoma* – this neoplasm usually manifests itself as lymphoid-like growths or tumors in the heart, abomasum, uterus, and lymph nodes but can be found in any tissue. (9 CFR 311.11(b))
>
> *Mesothelioma* – this neoplasm forms nodules or growths on the surfaces of the visceral organs and the lining of the abdominal cavity.
>
> *Neurofibroma* (nerve sheath tumor) – this neoplasm usually presents itself as small, firm, pearl-like nodules on the heart and along the nerves in the chest cavity, particularly between the ribs.
>
> *Adrenal tumors* – these neoplasms usually present as a variably sized mass that has replaced or grown alongside the adrenal gland just anterior to the kidneys.
>
> *Ovarian or uterine neoplasms* are fairly common in old cattle. They usually present as variably sized masses growing in or on the ovaries or uterus.

Pigmentary changes are sometimes found while performing viscera inspection. The following are the most common pigmentary conditions. (9 CFR 311.13)

Xanthosis – as was discussed in head inspection, this condition is found in the muscle tissue of older animals, especially the cheeks, heart, and esophagus. You would have all affected tissues removed and condemned. If you believe it is generalized, retain for veterinary disposition.

Melanosis – this condition is created by the abnormal deposition of the melanin pigment in various tissues. It is most commonly found in the lungs and liver. You would have all affected tissues removed and condemned. If you believe it is generalized, retain for veterinary disposition.

Icterus – this condition presents as a yellow discoloration of all visceral and carcass tissues. Retain for veterinary disposition.

Inflammatory conditions – There are various types of inflammatory conditions which may be observed while performing viscera inspection. (9 CFR 311.16) The most common are:

Enteritis - the small intestines may appear dark red to purple; this would indicate a condition called enteritis. The determination whether the condition is acute or chronic must be made. If acute, the carcass and parts must be retained.

Pneumonia and *pleuritis* are the most common abnormalities observed. Acute pneumonia is characterized by enlarged, edematous lymph nodes and/or dark red to purple sections or spots in the lung tissue. Retain this carcass and all parts for disposition. A chronic pneumonia may be characterized by a localized abscess within the lungs, or many times evidence that the lung has become adhered to the pleura (lining of the thoracic cavity), frequently called pleuritis. You will retain the carcass and all parts upon detecting a generalized condition. When the condition is strictly localized, the lungs would be condemned, as well as any contaminated organs, and the carcass retained for removal of any adhesions that may be present.

Pericarditis - (inflammation of the pericardium or heart sac) - If the condition is acute, or there are secondary changes to the carcass and other organs, the carcass and parts must be retained for the veterinarian.

Endocarditis (inflammation of the endocardium or inner lining of the heart) – any other changes in the carcass or viscera would require the carcass and parts to be retained for the veterinarian.

Peritonitis (inflammation of the lining of the abdominal cavity) – If acute, extensive, or there are secondary changes, the carcass and parts must be retained for the veterinarian.

Metritis (inflammation of the uterus) - may vary from a slight redness or odor in the uterus or pyometra (metritis), to a retained placenta or fetus. In these instances you should evaluate the degree of involvement, the remaining viscera condition, and the carcass condition.

Adhesions may be seen with any of these conditions. Adhesions are simply a chronic reaction to inflammation in which the surfaces of two or more organs are connected by fibrous connective tissue.

If any of the above inflammatory conditions appears localized, or chronic, and no further carcass or viscera involvement is observed, the abdominal viscera would be condemned and the carcass retained for trimming.

Some conditions that you may see in the muscular tissue of the heart, esophagus, or diaphragm are:

Cysticercosis – as was discussed under head inspection, beef tapeworm cysts may be seen in any muscle tissue at inspection but is most commonly seen in the active muscles such as the cheeks, heart, esophagus, and diaphragm. Retain the carcass and parts for veterinary disposition. (9 CFR 311.23)

Eosinophilic myositis (EM) – as was discussed under head inspection, this condition presents as variable sized areas of muscle discoloration most commonly affecting the heart, cheeks, diaphragm, esophagus, or tongue. If it is suspected to be generalized, retain the carcass and parts for the veterinarian. (9 CFR 311.35)

An infectious disease process, if not contained by the animal's defenses, may result in pathogenic bacteria and their associated by-products circulating in the bloodstream creating a condition called septicemia.

Septicemia--a generalized inflammatory condition caused by pathogenic bacteria and associated toxins in the blood. Most, or all, of the body lymph nodes may be enlarged, hemorrhagic, and edematous. Kidneys may have petechiae (small pinpoint hemorrhages). Other pathology may be present. Retain the carcass for veterinary disposition. (9 CFR 311.16(a)(2) and 311.17)

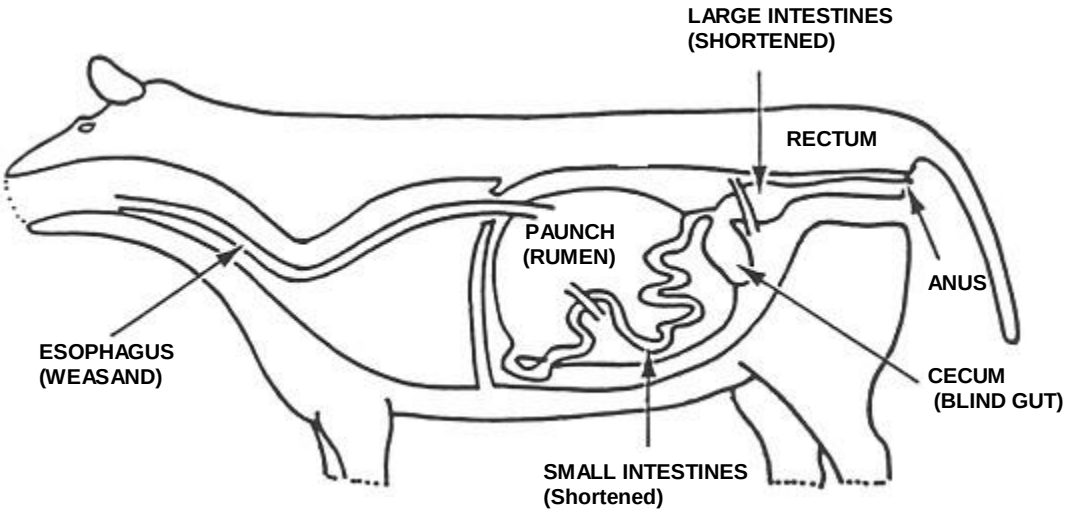

4. CATTLE ABDOMINAL VISCERA

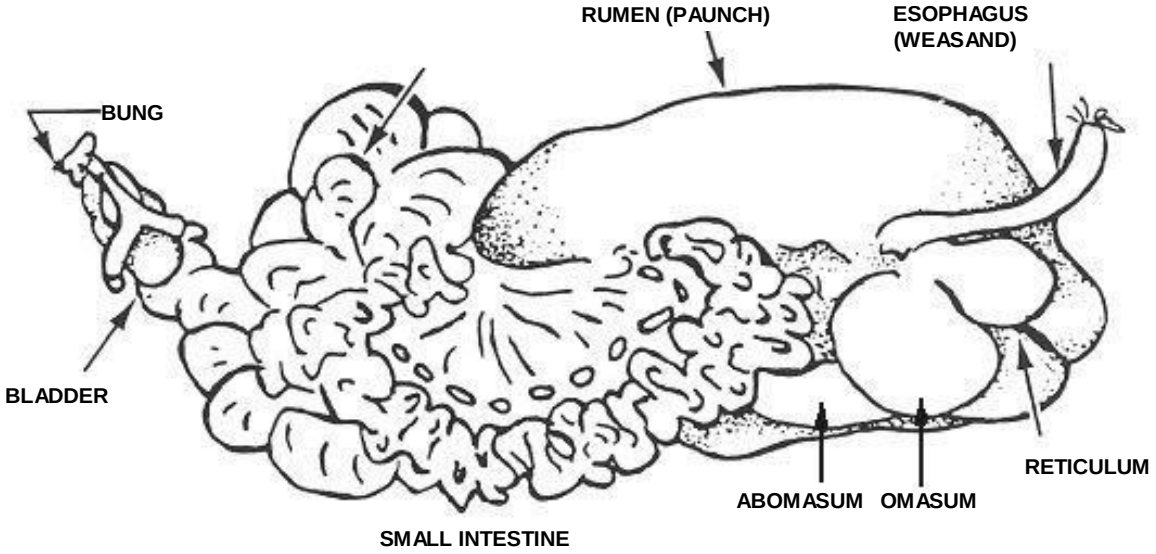

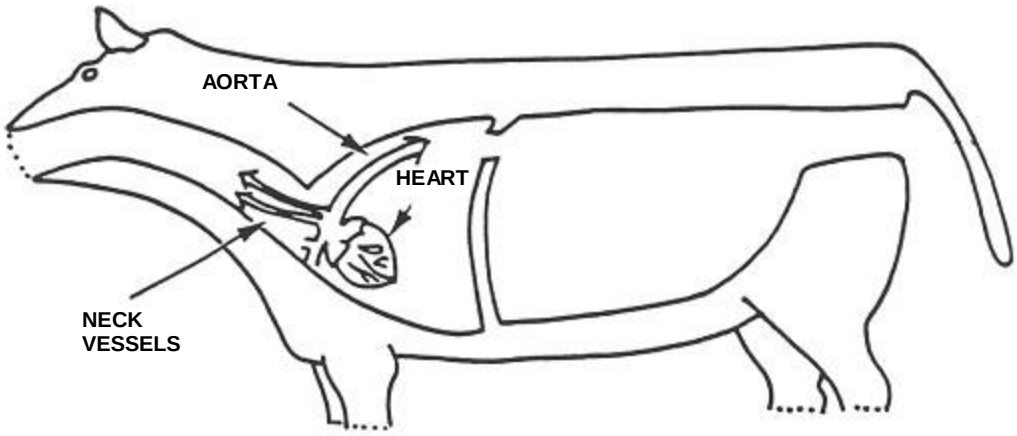

3. CATTLE LUNGS AND HEART (PLUCK)

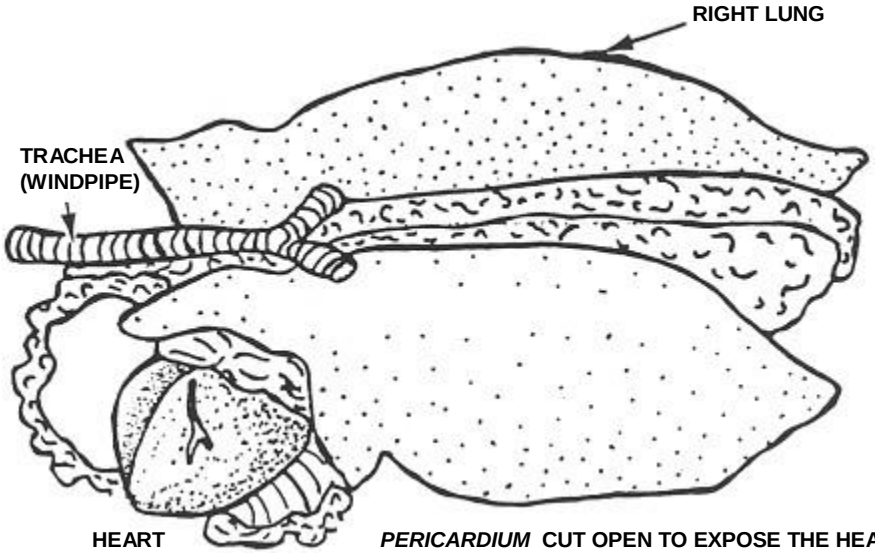

HEART (LEFT SIDE)

***PERICARDIUM* CUT OPEN TO EXPOSE THE HEART. THE PERICARDIUM IS A TOUGH MEMBRANOUS SAC SURROUNDING THE HEART.**

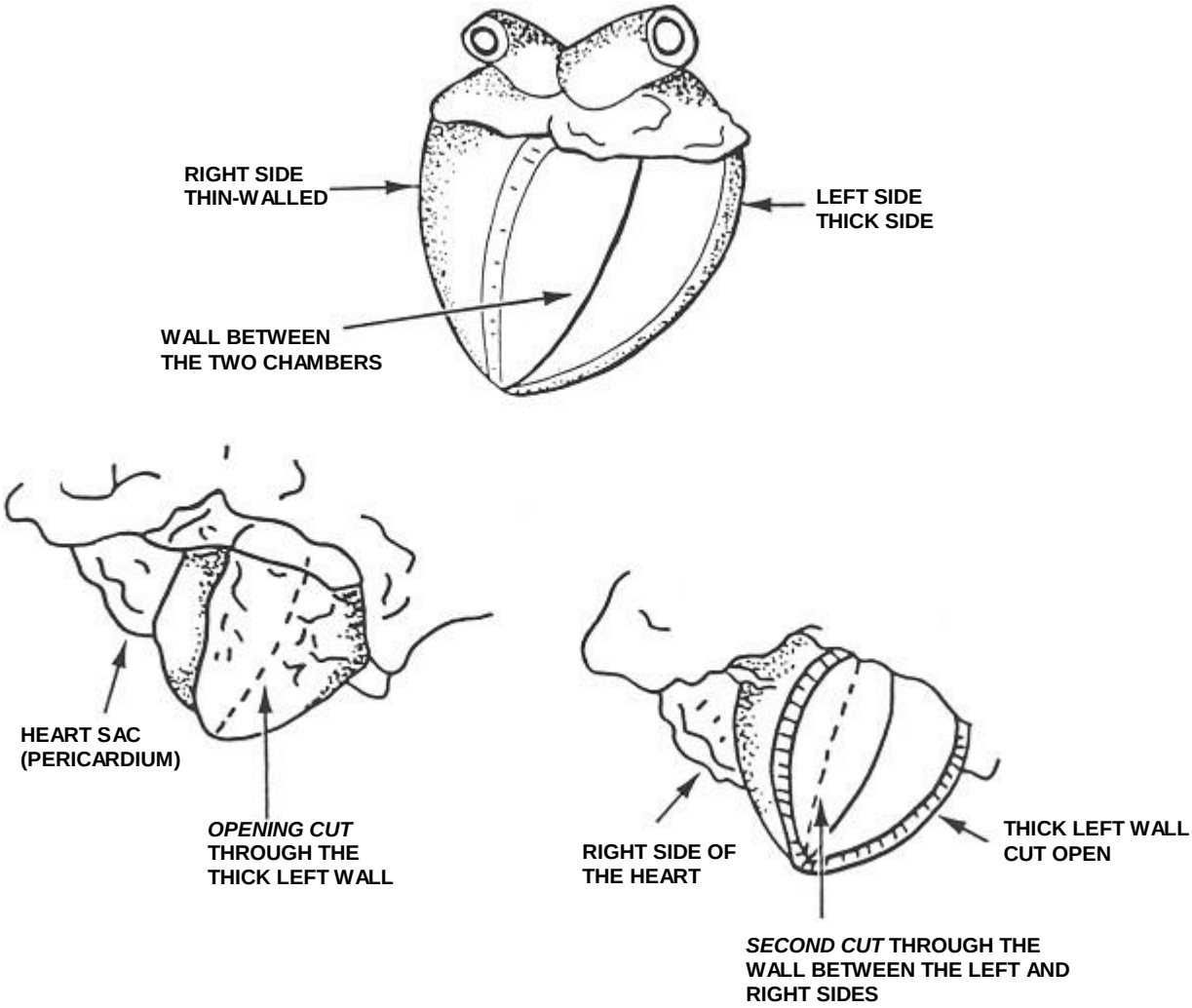

Liver Conditions

Here are the most commonly seen conditions that affect the liver.

Abscess - an abscess may appear on the surface and be quite obvious, or it may be located under the surface, and only detected when you palpate properly. You may make as many incisions as you feel necessary to search for abnormal conditions, but remember you should not unnecessarily mutilate product. In *all* cases, a liver containing an abscess is condemned as not fit for human consumption. Benign abscesses (non-malignant and judged *not* to be affecting surrounding tissue) may be salvaged for animal food *after* removal of the abscess itself. Abscesses may be associated with specific diseases, but are usually seen as localized conditions. Many feedlot (fat) cattle have localized abscesses and the cause seems to be related to high-energy cereal diets, with unsanitary feedlot conditions also a factor. (9 CFR 311.14)

Telangiectasis and *Sawdust* - The condition in which a liver has pinkish-white to yellow-gray necrotic (dead) spots that make the liver appear as if sawdust had been sprinkled or scattered through it is called "sawdust." The area around the spots appears normal and the liver's surface over the spots is usually smooth. The condition in which a liver has purple-red to bluish-black spots present both on the surface as well as throughout the organ is called telangiectasis and is referred to as "telang." Usually the surface of the liver is slightly depressed when affected with telang. (9 CFR 311.31)

To determine the disposition of sawdust and telang conditions, *three* degrees of involvement are used.

1. Slight: Where the lesions are small in size and slight in number. A liver meeting the slight criteria is passed for food without restriction.

2. More severe than slight but involves *less* than one-half of the organ: The portion of the liver that is *not* affected or only slightly involved may be passed for food without restriction, while the remainder of the liver is condemned.

3. More severe than slight and involves *more* than one-half of the organ: The entire organ is condemned. (It may be salvaged for animal food.)

Liver Flukes (Distoma) - the appearance of a fluke infested liver depends a great deal on the amount of fluke infestation. A slight infestation will probably not affect the liver tissue as such. A heavy infestation may cause a cirrhotic effect on the organ, with the surface becoming scarred. Many times, there are bumpy, raise and/or depressed areas, and sometimes a discoloration showing dark blue to black sections on and within the tissue. The liver may take on a "hobnail appearance." (9 CFR 311.25)

The primary purpose in opening the bile duct during liver inspection is to detect flukes. When there is a fluke infestation the bile duct may be thickened and frequently you will observe live flukes. The three liver flukes most often seen in domestic cattle today are: *Fascioloides magna* (Deer fluke); *Fasciola hepatica* (Cattle fluke)*; Dicrocoelium dentricum* (Lancet fluke).

In all cases of liver fluke infestation the liver is condemned and not eligible for human consumption. The liver *may* be salvaged and used for animal food.

Carotenosis - a liver with carotenosis is characterized by a highly colored yellow-orange color or pigmentation. This condition is quite common in cattle livers and may cause the liver to become enlarged, soft, and friable (easily crumbled). Here’s a practical test to assure the correct recognition of carotenosis. The test is made by placing a white paper towel or napkin on the cut surface of a liver suspected of being affected with carotene discoloration. An orange-bronze stain would be indicative of carotenosis. The liver is condemned and not eligible for use a human food but *may* be salvaged for animal food uses. The pale-colored liver found in near-term cows may resemble carotenosis. For this reason you must be sure of your diagnosis. The pale liver may vary from tan to yellow to gray in color and may be enlarged. Usually the cut surface feels greasy. The cause of this pale liver is thought to be the result of a change in fat metabolism of the near-term cow. Livers from cattle that are normal except for the pale color are passed without restriction. (9 CFR 311.13)

Hydatid Tapeworm Cyst - hydatid cysts may occasionally affect livestock. Most domestic food animals are the intermediate host for this tapeworm cyst, which usually is a result of the tapeworm (*Enchinococcus granulosus*) of dogs. While the animal eats or grazes, it consumes the eggs, probably deposited by the dog, and the eggs in turn change to larvae in the food animal's system. The larvae then end up in various organs via the blood stream. The cyst will vary in size but may be as large as two to four inches in diameter. The fluid inside the cyst is usually clear and colorless. You must be careful not to confuse the hydatid cyst with an accessory gall bladder.

The organ or part affected with a hydatid cyst is condemned and is *not* suitable for use in animal food. (9 CFR 311.25)

Some other conditions that may be seen in liver inspection are:

Cirrhosis - characterized by degeneration of liver tissue with a replacement by hard, tough, fibrous connective tissue. Condemn these livers and the establishment may save them for animal food.

Chronic Passive Congestion (Blue Livers) - the presence of large amounts of blood in the liver with resulting degenerative changes. Condemn these livers and the establishment may save them for animal food.

Melanosis – melanin deposits of varying size are present in the liver. Condemn these livers and the establishment may save them for animal food.

Green Liver Syndrome – the liver and hepatic nodes are colored green due to abnormal deposition of a metabolic by-product of nucleic acid metabolism. Condemn these livers and the establishment may save them for animal food.

Fatty Liver - seen mostly in pregnant cows as a result of fatty deposition in the liver. The liver will be pale in appearance. These livers may be passed for food.

Control of Condemned Livers

Those livers that *are* condemned, but which the company has indicated it wishes to salvage for animal food, must be handled properly before they may be shipped from the establishment as animal food livers. Here is a summary of the steps to take.

1. The livers must be marked "U.S. Condemned."

2. The condemned livers may be held in containers on the slaughter floor, or may be worked as inedible product during the slaughter procedure.

   a. When the condemned livers are placed in a container, the container must be plainly marked "inedible." Ensure that the product in these containers is maintained under security at *all* times. This means under your direct supervision, or locked or sealed in a container with an official device until such a time that the product *is* properly denatured.

b. When the establishment requests an opportunity to slash and denature the condemned livers during the slaughter operation, it *may* be done, provided it doesn't create problems of control, security, or contamination.

Liver Disposition Chart

Disease or Condition	Degree	Disposition
Telangiectasis Sawdust Spotted	Slight	Pass for human food
	The affected portion trimmed when less than 1/2 of liver is more than slight	Condemn/Use for animal food
	Balance of this liver is slight or less	Pass for human food
	More than slight involving 1/2 or more of liver	Condemn/Use for animal food
Contamination	Excessive	Condemn/Tank
Cirrhosis	Any amount	Condemn/Use for animal food
Nonmalignant change	Any amount	Condemn/Use for animal food
Abscesses-benign (trim)	Localized - Affected area	Condemn/Tank
	Localized - Non-affected area	Condemn/Use for animal food
Flukes	Any evidence of infestation	Condemn/Use for animal food
Hydatid Cyst	Any amount	Condemn/Tank
Abscesses (Not benign)	More than localized	Condemn/Tank
Carotenosis (yellow)	Any amount	Condemn/Use for animal food
Other Parasites	Numerous lesions and cannot be removed	Condemn/Use for animal food
	Localized: Affected area trimmed	Condemn/Use for animal food
	Localized: Non-affected area	Pass for human food

References: Regulation 311.25
Regulation 311.31
Regulation 314.10

Kidney Conditions

The kidneys may be presented with the viscera or presented with the carcass. As a matter of convenience, we will cover kidney conditions here.

Cystic kidneys – in this condition the kidneys have fluid-filled cysts visible on the surface of the organ or occasionally embedded inside. Slight cystic conditions may be trimmed and passed. When the cystic condition is more than slight, the kidneys are condemned.

Nephritis is an inflammation of the kidney and is usually characterized by swelling, off-color, or abscess. As a general rule nephritis is a secondary cause resulting from other disease conditions within the animal. When the urinary tract, bladder, and other organs show signs of involvement, the carcass should be retained (including the viscera if available) for the veterinarian to make a final disposition. If the nephritic condition is considered localized or chronic, the kidney is removed and condemned, and the carcass passed.

Lymphocytic infiltration is a condition usually found in calves in which there are white streaks or spots in the kidney tissue. Kidneys with marked or extensive lymphocytic infiltration (white spots or streaks) are to be condemned. Those with slight streaks or a few spots may be passed without restriction.

Remember, if conditions are found that may result in the condemnation of the carcass or parts, retain the carcass and parts by identifying them with a retain tag and direct establishment employees to remove them to the disposition area for inspection by the veterinarian. If conditions are found that are not wholesome but would not result in condemnation of the carcass, direct their removal by the establishment employee.

***FEMALE* URINARY TRACT**

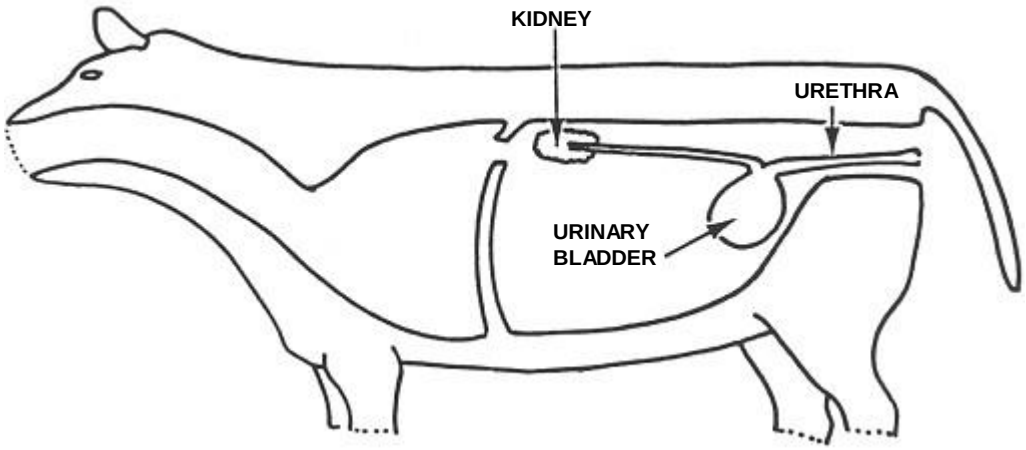

MALE **URINARY TRACT**

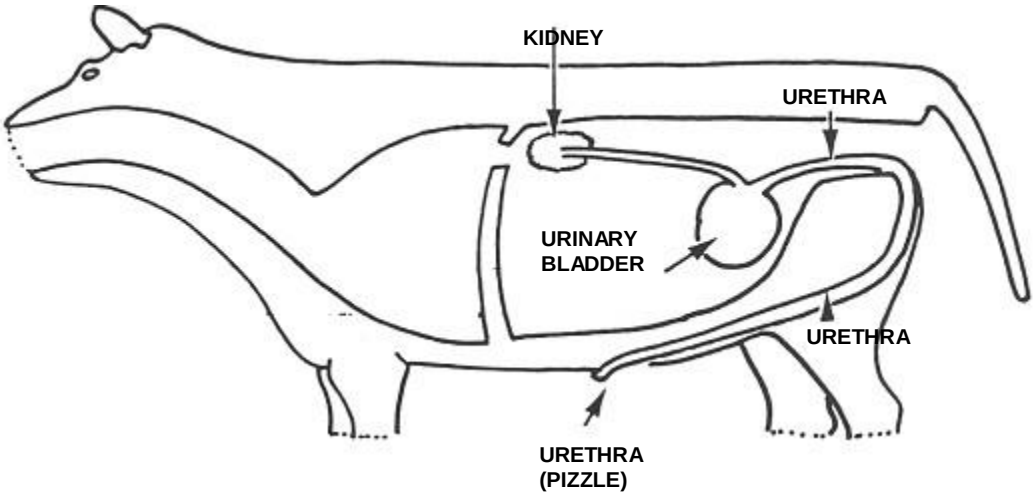

Presentation

During the evisceration procedure several improper presentations may occur. The following are examples:

The liver may be placed with the parietal surface up.
The hepatic (portal) lymph nodes may be missing from the liver.
The bladder may be leaking urine onto exposed surfaces of the carcass or viscera.
The paunch or intestines may be cut or broken, causing contamination.
The pluck may be placed upside down (ventral surfaces of the lungs pointing up).
The liver, pluck, and viscera, or any one of these organs, may be pushed to or deposited on the opposite side of the table from your station, or literally missing.

There are many other examples of improper presentation. Generally, if an improper presentation occurs infrequently, delay inspection long enough to complete inspection duties. Also require that any contamination be removed. *A very important consideration is that your attention to the actual inspection procedures must not be distracted.* You may miss something you need to see.

If any improper presentations occur frequently, delay inspection, and meet with establishment management in an effort to get the problem(s) under control. *Your attention must not be distracted during the inspection procedure.*

Carcass Inspection

Almost all establishments handle the carcass the same way until the time the head is removed. Once the head is removed however, any one of several methods may be used to complete the carcass dressing. Almost all the different methods being used today are variations of two basic operations. One of those basic methods is called a "bed" dress operation. The other is called an "on-the-rail" operation. The bed dress method is by far the oldest method and probably dates back to the time when animals were "field dressed". This method is still widely used; however, it is most often used in the low-volume establishments. After the head has been removed, the carcass is lowered to the skinning bed. The skinning bed may be a cradle or it may be the floor. The "on-the-rail" method was designed with volume in mind. The animal is moved around the slaughter floor by means of a rail and instead of one employee dressing the entire animal, several specialists will perform their jobs as the carcass moves past them.

In either dressing method there are several sanitary dressing requirements you need to be alert to. First, *all* grubs, contamination, bruises, etc., *must* be trimmed from the back of the carcass in the path the saw is to proceed, before splitting.

Secondly, even though it is not required that the saw be sanitized after each use on normal carcasses, it *must* be sanitized when used on a retained carcass or when a hidden abscess or other pathology is contacted.

The two halves are moved to the carcass (rail) inspection station. The establishment is responsible for assigning an employee prior to the inspection station to trim and remove all bruises, blood clots, grubs, and the like. The establishment employee must *not* remove any abnormality that could affect the disposition of the carcass.

Frequently in the bed dress operation, the carcass will be trimmed and rail inspection accomplished by the viscera inspector while the split carcass is in the same area where it was eviscerated.

After the rail inspection is completed the carcass will be moved, or proceed on the chain, to the final wash area.

Any carcasses located on the "final" rail must be physically separated from other carcasses. This will prevent cross-contamination from one carcass to another. In no case will a retained carcass be washed or trimmed unless authorized by a program employee.

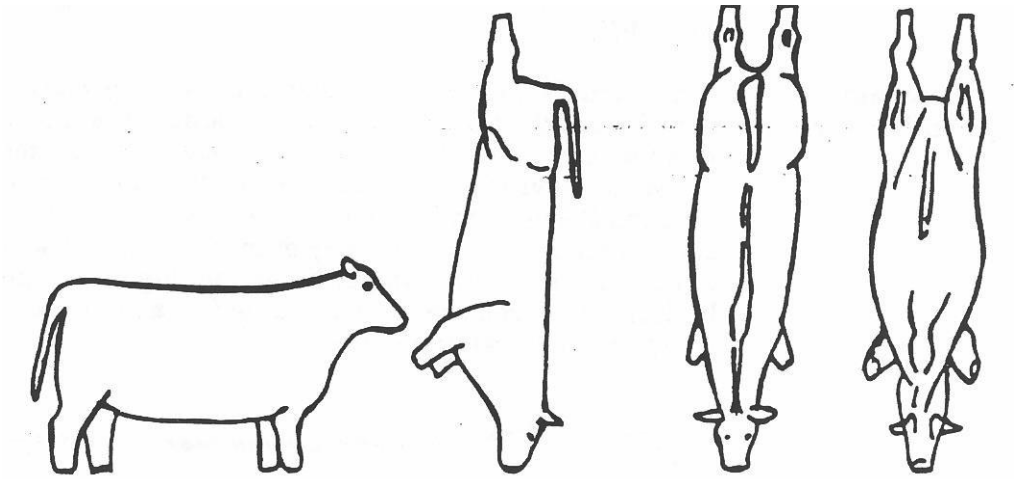

STANDING **SIDE** **BACK** **BELLY**

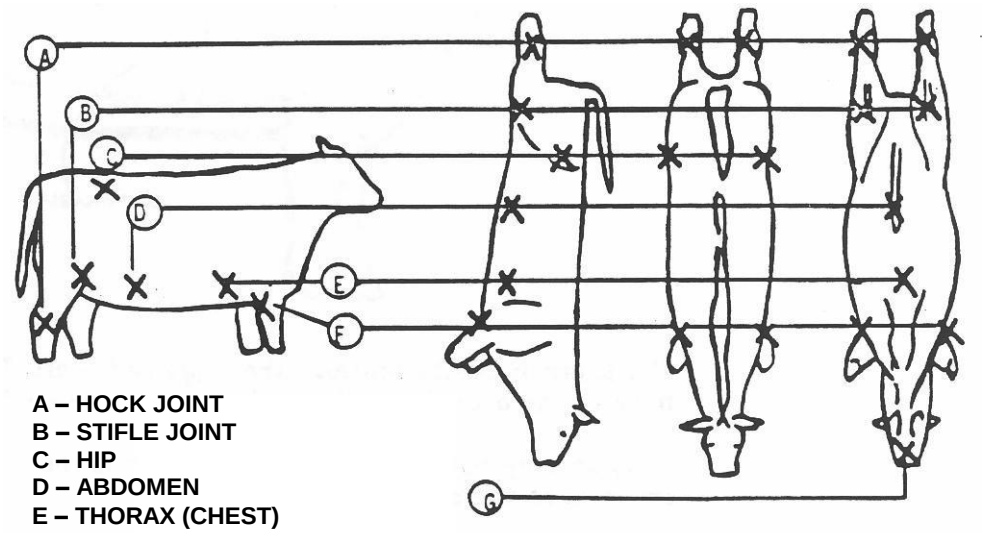

KEY:

A – HOCK JOINT
B – STIFLE JOINT
C – HIP
D – ABDOMEN
E – THORAX (CHEST)
F – ELBOW JOINT
G – LOWER JAW

Lymph Nodes

Learn the names and locations of these lymph nodes.

1. Scrotal (superficial inguinal)

2. Mammary (supramammary)

3. Medial (internal) iliac

The scrotal lymph node is found on the male, and the mammary lymph node is found on the female. The medial iliac lymph node is found on the inside of the abdominal cavity, and the other two are found on the outside of the body cavities.

The following steps are those to follow when inspecting the carcasses in a smaller establishment where the procedures are divided into hindquarter and forequarter inspection.

Hindquarter inspection – performed during and immediately after evisceration.

1. Observe back of skinned carcass while eviscerated.
2. Palpate scrotal (superficial inguinal), or mammary (supramammary), and medial iliac (internal iliac) lymph nodes.
3. Observe body cavities.

Forequarter Inspection – performed during and immediately after evisceration.

1. Observe cut surfaces of muscles and bones, diaphragm's pillars and peritoneum.
2. Observe and palpate kidneys and diaphragm.
3. Observe pleura, neck and carcass exterior.

The following steps are those to follow when inspecting the carcasses in a larger establishment where the carcass inspection procedures are performed in a single sequence at a rail inspection station.

Carcass Inspection

1. Palpate superficial inguinal, or supramammary, and internal iliac lymph nodes. Observe lumbar region.
2. Observe and palpate kidneys.
3. Observe diaphragm's pillars and peritoneum.
4. Observe and palpate diaphragm.
5. Observe pleura, cut surfaces of muscles and bones, neck, and carcass exterior.

You are usually doing two dexterity actions during each step. For example, you are required to *observe* and *palpate*, or *incise* and *observe*.

If you observe conditions of improper presentation, require the establishment employee to remove the condition before the carcass leaves the carcass inspection area. Examples of improper presentation are kidneys not exposed; presence of surface contaminants such as hide, hair, or pus; and lymph nodes not presented for inspection.

Diseases and conditions that you may observe during carcass inspection include the following:

Arthritis – is an inflammatory condition of the joint. Swollen joints would usually be associated with an arthritic condition. Most arthritis is the result of an injury and only requires that the affected joint and corresponding lymph nodes be removed and condemned. However, if during the removal of affected joints the fluid within the joint is released, all tissue in contact with the fluid must also be trimmed away and condemned. When more than one joint is involved with arthritis, you would have to consider the possibility that an infection or blood condition may have caused the swelling and that a generalized condition may exist. In the case of polyarthritis (more than one joint affected with arthritis) you should retain the carcass for veterinary disposition. (9 CFR 311.7)

Abscesses – may be found in any location on the carcass. In most instances, you would have the affected tissues, including any exudate, removed and the carcass passed. However, if you suspect the condition may be generalized, retain it for veterinary review. (9 CFR 311.14)

Bruises / Injuries – may be found in any carcass location. In the vast majority of cases you would have the affected tissues removed and pass the carcass. (9 CFR 311.14)

Pleuritis / peritonitis – as discussed in viscera inspection, you may see inflammatory conditions affecting the pleural and peritoneal linings. If the inflammation is not acute and extensive and there is no generalized effect on the carcass, you would have the affected tissues removed and the carcass passed. (9 CFR311.16)

Adhesions represent a chronic situation in which the pleuritis or peritonitis has been resolved by the formation of fibrous connective tissue. Usually the viscera inspector has observed the organ that had adhered to either of these cavities and has indicated, by tagging, the degree of involvement. If the condition is determined to be localized, you would require the rail trimmer to remove *all* evidence of adhesions.

Neoplasms (tumors) – as discussed in viscera inspection, you may see various types of neoplasms. The most common types of neoplasms in cattle are malignant lymphoma, mesothelioma, and adrenal tumors. (9 CFR 311.11)

Pigmentary conditions – as discussed in viscera inspection, you may see the following pigmentary conditions at carcass inspection. (9 CFR 311.13)

> *Xanthosis* – observed as a brown discoloration of muscle tissue. Most commonly found in the cheeks and heart. It may be seen in the carcass musculature. If you suspect it is generalized, retain for veterinary disposition.
>
> *Melanosis* – observed as a black pigment in various tissues. If you suspect it is generalized, retain for veterinary disposition.
>
> *Icterus* – a yellow discoloration of all tissues including connective tissues. Retain for veterinary disposition.

Cysticercosis – beef tapeworm larval cysts may be seen in carcass musculature. Retain these for veterinary disposition. (9 CFR 311.23)

Hypoderma larvae (Grubs) – these fly larvae may be found primarily along the midline of the back in early spring. All grubs (Hypoderma bovis) and/or the evidence of grubs must be trimmed, leaving only normal tissue. (9 CFR 311.25)

Eosinophilic Myositis – muscular lesions, as discussed in the section on head inspection, may be observed in the carcass musculature at carcass inspection. If you believe it to be generalized, retain for veterinary disposition. (9 CFR 311.35)

Steatosis – a condition in which muscle tissue is infiltrated and replaced by fat tissue. Normally this is a localized condition which can be trimmed. (9 CFR 311.35)

Fat necrosis – A condition that at times may appear to be serious but actually is not. There may be a chalky white substance throughout the kidney fat and on up through the renal area. There are times when the necrosis may appear imbedded or inside the fat. A related condition is -cheesy brisket‖. This condition called pre-sternal calcification is usually caused by the rubbing or bumping of the animal's breast against the feed bunk. The significance is slight as far as the overall acceptability of the carcass is concerned. The condition would be removed by trimming, and unless other conditions are present, the carcass passed without restriction. (9 CFR 311.35)

Emaciation – is a condition in which the carcass has reached a state of degeneration due to lack of nutritional input. There will be no normal fat and the musculature will be moist and glassy. You may see a watery material running down the backbone and dripping off the neck after the carcass is split. This material is represents a serous fatty degeneration. Do not confuse a normally thin carcass for emaciation. Retain carcasses in which you suspect emaciation for veterinary disposition. (9 CFR 311.26)

Septicemia--a generalized inflammatory condition caused by pathogenic bacteria and associated toxins in the blood. Most, or all, of the body lymph nodes may be enlarged, hemorrhagic, and edematous. Kidneys may have petechiae (small pinpoint hemorrhages). Other pathology may be present. Retain the carcass for veterinary disposition. (9 CFR 311.16(a)(2) and 9 CFR 311.17)

Mastitis – is an inflammatory condition of the udder. The udder will usually be removed prior to inspection but signs of inflammation and even cellulitis can often be seen in the attachment area of the udder and the regional lymph nodes may be enlarged. Retain the carcass for veterinary disposition if there are generalized signs. (9 CFR 311.16)

Cellulitis - is an inflammatory condition of the subcutaneous tissues which may extend into the muscle. Causes are wounds, injections, surgery, mastitis, or any other means of bacteria being introduced into the tissues. Retain the carcass for veterinary disposition if there are generalized signs. (9 CFR 311.16)

Injection Lesions – are sometimes found in the neck, flank, hip, or rump areas. If lesions have the appearance of being recent, retain the carcass for residue testing and subsequent veterinary disposition. (9 CFR 311.39)

As stated earlier, if you observe a disease or condition that may result in condemnation of the carcass, retain the carcass and its parts for veterinary disposition. For example, tag each half-carcass, request that the viscera and head be retrieved, and apply one tag to each. If you observe a disease or condition that will not result in the condemnation of the carcass, direct the removal of the disease or condition by an establishment employee.

Products, parts, etc., that are removed and condemned for various reasons are usually placed in a container near the rail inspector and the viscera inspector. These containers must be properly identified for their intended purpose (e.g., condemned inedible). The inspector who is responsible for the area where the containers are located must also be responsible for seeing that the containers are either locked, sealed with an official seal, or under visual security at all times. You would not leave the area before the container was locked, sealed, or the material was denatured or destroyed for human food purposes.

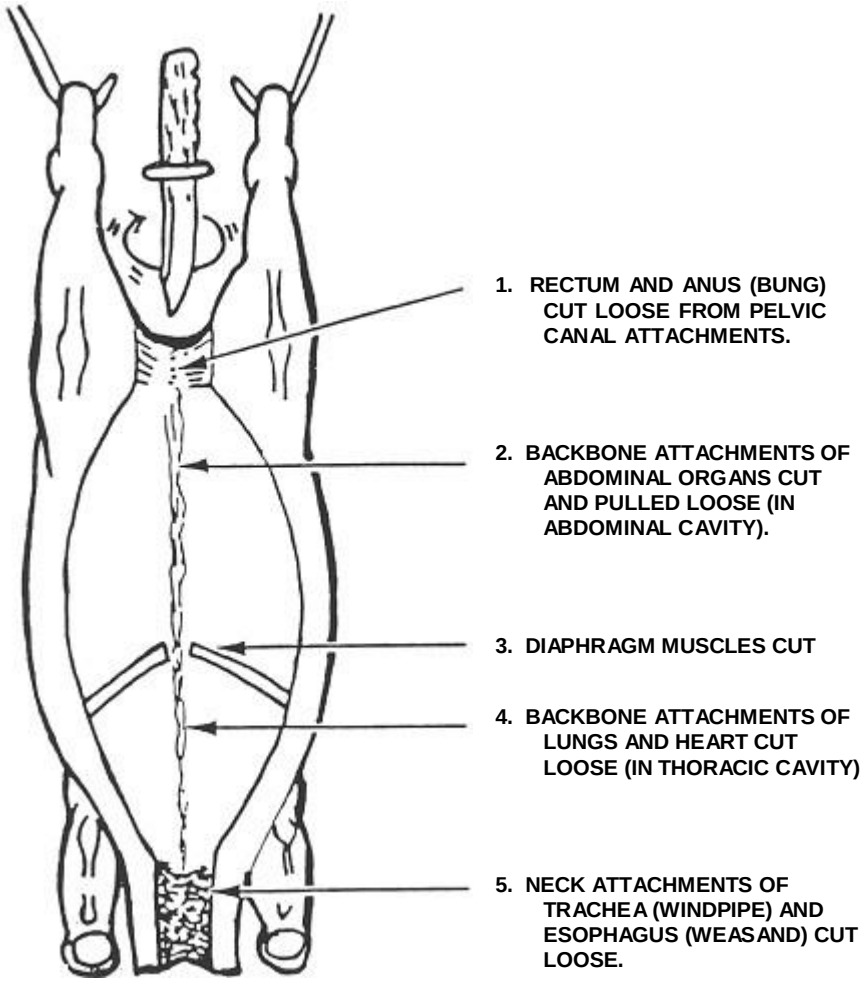

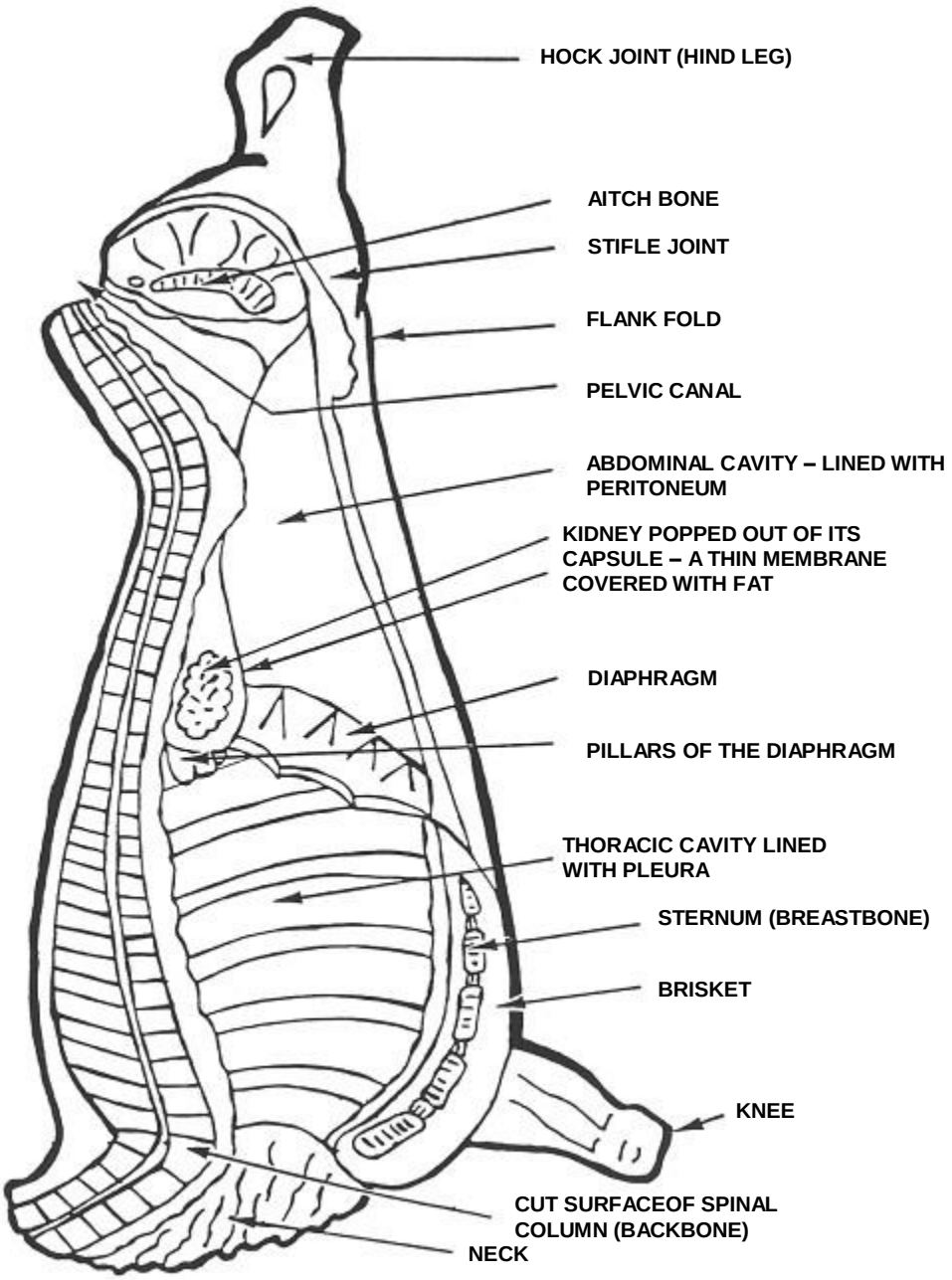
HOCK JOINT (HIND LEG)
AITCH BONE
STIFLE JOINT
FLANK FOLD
PELVIC CANAL
ABDOMINAL CAVITY – LINED WITH PERITONEUM
KIDNEY POPPED OUT OF ITS CAPSULE – A THIN MEMBRANE COVERED WITH FAT
DIAPHRAGM
PILLARS OF THE DIAPHRAGM
THORACIC CAVITY LINED WITH PLEURA
STERNUM (BREASTBONE)
BRISKET
KNEE
CUT SURFACEOF SPINAL COLUMN (BACKBONE)
NECK

LEFT SIDE OF CARCASS

LEFT SIDE OF CARCASS

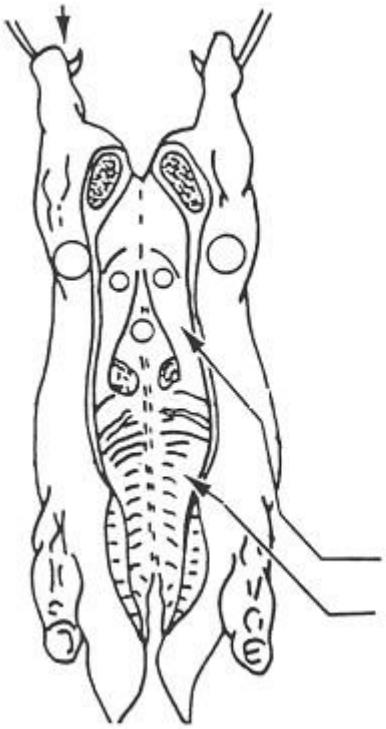

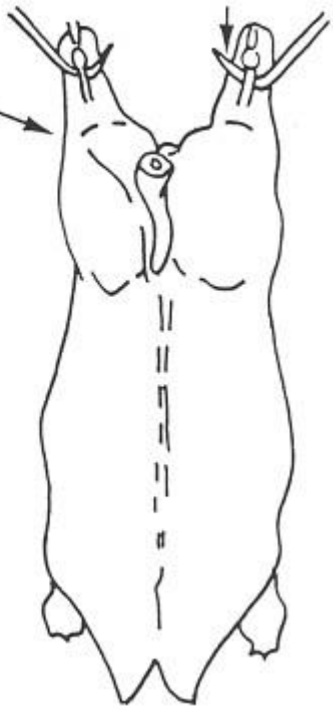

1. OBSERVED BACK OF SKINNED CARCASS.

2. PALPATE LOCATION OF THE SCROTAL (SUPERFICIAL INGUINAL) OR MAMMARY (SUPRAMAMMARY) LYMPH NODES

3. PALPATE THE MEDIAL (INTERNAL) ILIAC LYMPH NODES.

4. OBSERVE THE LUMBAR REGION

5. OBSERVE THE BODY CAVITIES ABDOMINAL THORACIC

***THEN* THE VISCERA FROM THIS CARCASS IS INSPECTED. THEN –**

LEFT HALF OF CARCASS – INSIDE VIEW

LEFT HALF OF CARCASS – OUTSIDE VIEW

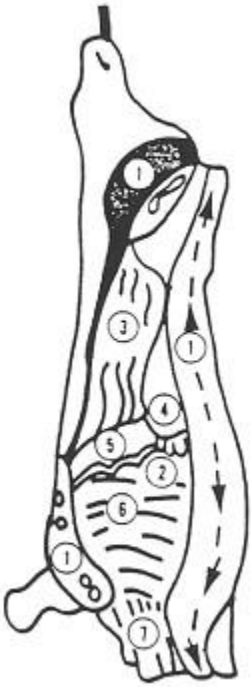

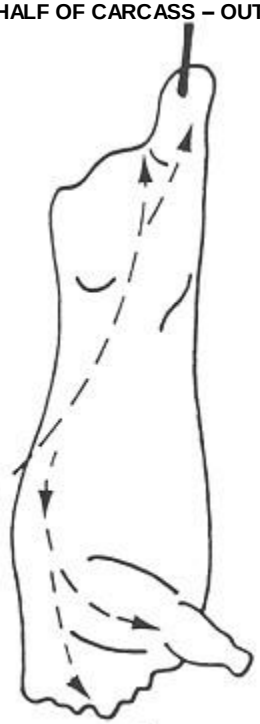

1. OBSERVE CUT SURFACE OF MUSCLE AND BONE

2. OBSERVE PILLARS OF THE DIAPHRAGM

3. OBSERVE PERITONEUM (LINING OF THE ABDOMINAL CAVITY)

4. OBSERVE AND PALPATE KIDNEY

5. OBSERVE THE PLEURA (LINING OF THE THORACIC CAVITY)

6. OBSERVE THE NECK MUSCLES

7. OBSERVE OUTSIDE OF CARCASS

SAME HALF – INSIDE AND OUTSIDE

LEFT HALF OF CARCASS – OUTSIDE VIEW

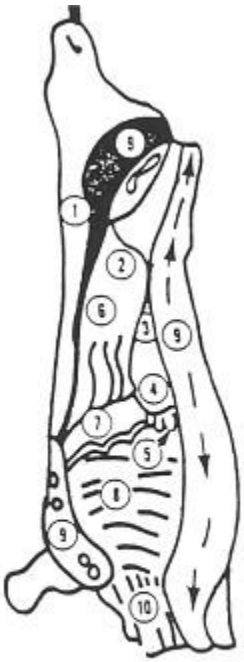

1. PALPATE THE SCROTAL (SUPERFICIAL INGUINAL) OR MAMMARY (SUPRAMAMMARY) LYMPH NODES

2. PALPATE THE MEDIAL (INTERNAL) ILIAC LYMPH NODES

3. OBSERVE THE LUMBAR REGION

4. OBSERVE AND PALPATE THE KIDNEYS

5. OBSERVE THE PILLARS OF THE DIAPHRAGM

6. OBSERVE THE PERITONEUM

7. OBSERVE AND PALPATE THE DIAPHRAGM

8. OBSERVE THE PLEURA

9. OBSERVE THE CUT SURFACES OF MUSCLES AND BONES.

10. OBSERVE THE NECK MUSCLES

11. OBSERVE THE OUTSIDE OF THE CARCASS.

LEFT HALF OF CARCASS – OUTSIDE VIEW

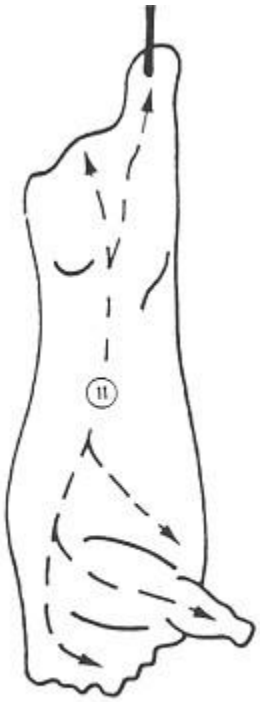

SAME HALF – INSIDE AND OUTSIDE

Inspection Procedures for Other Livestock Species

In the Appendix, you will see a summary of the inspection procedures for calves, sheep and goats, and equines.

Restricted Products

The livestock slaughter regulations outline requirements related to restricted products (9 CFR 315). A restricted product is defined as any meat or meat food product that has been inspected and passed but cannot be released for human consumption until it has been subjected to a required treatment because it has a disease or condition that might be transmitted to humans if the meat is not treated. There are four types of restricted product treatments. They are:

Refrigeration (9 CFR 311.23(a)(2))
Heating (9 CFR 311.23(a)(2))
Cooking (9 CFR 311.2(d)(f)(g), 311.18(e), 311.24, 311.25)
Use in comminuted cooked meat food product (9 CFR 311.20(b), 311.35(c), 311.37)

Restricted product will be used for human food after required treatments are complete. For this reason, condemned and inedible products are not examples of restricted product.

The establishment must maintain control over all restricted product. FSIS inspection personnel must verify that the establishment has met the conditions associated with the restrictions before this type of product is allowed to be used as human food. Failure to adequately control certain products may result in the transfer of disease or pathogen from the product to the consumer.

Control of any restricted product begins at the time the veterinarian makes a disposition. First, a decision is made to pass the carcass with a restriction. A thorough check is made to see that all visible lesions are removed from the carcass (9 CFR 311.23). Then, the carcass is retained. If any additional lesions are discovered at a later time (while the carcass is being boned for example), the veterinarian will make a new disposition based on the new findings.

Some establishments have adequate facilities for treating restricted product (e.g., cooking, freezing). For establishments that do not have such facilities, the establishment is allowed by regulation to ship restricted product to another official establishment that has the needed facilities (9 CFR 316.18). To maintain security, the restricted product must be shipped under official government (FSIS) seal.

Let’s review each of the four categories involving restricted product.

Passed for Refrigeration

Only carcasses that are moderately affected with beef cysticercosis (beef measles) may be passed with a refrigeration restriction (9 CFR 311.23(a)(2)). This actually means the

carcass or boned meat must be frozen. Freezing this product destroys any tapeworm cysts that were not identified and removed during inspection.

Passed for Heating

There are two conditions that may be "Passed for Heating" by the veterinarian. One is cysticercosis of sheep (sheep measles), the other cysticercosis of beef (beef measles) (9 CFR 311.23(a)(2)). Notice that beef measles may be passed for refrigeration or passed for heating. A cattle or sheep carcass, or meat derived from such carcasses passed with a heating restriction, must be heated throughout to a minimum internal temperature of 140 F.

Passed for Cooking

Carcasses with the following diseases or conditions may be "Passed for Cooking."

Tuberculosis (9 CFR 311.2)
Caseous lymphadenitis (9 CFR 311.18(e))
Swine cysticercosis (pork measles) (9 CFR 311.24)
Carcasses with parasites not transmissible to humans (9 CFR 311.25)

Carcasses passed for cooking must reach a minimum temperature of 170 F for not less than 30 minutes. These carcasses are marked with a "US Passed for Cooking" stamp by the veterinarian when he or she makes this disposition.

Passed for Use in Comminuted Cooked Product

The fourth group of restricted product consists of those carcasses passed for use in comminuted cooked product. There is a difference between this restricted product category and "Passed for Cooking." Passed for cooking requires subjecting the product to 170 F for not less than 30 minutes. There is not such a time/temperature requirement with product passed for comminuted cooked product. The only restriction imposed on these products is that they be used only in comminuted cooked products. Comminuted cooked food products are those that are finely ground and have a uniform appearance, such as frankfurters and bologna. These products are normally cooked at a temperature near 160 F.

There are two conditions for which carcasses may be passed for use in comminuted cooked product by the veterinarian. The first is certain carcasses affected with eosinophilic myositis (EM) (9 CFR 311.35(c)). The establishment may ship these carcasses prior to meeting the required restrictions. As with control of other restricted product, carcasses with EM passed for use in comminuted cooked product must be shipped under official seal.

The other products in this restricted category are boar carcasses with less than pronounced sexual odor (9 CFR 311.20(b), 311.37). As in the case with all restricted product, inspection must have positive control over these carcasses. A retain tag is used to identify carcasses passed for use in comminuted cooked product. If boar carcasses or parts with less than pronounced sexual odor are to be shipped elsewhere for boning, rendering, or use in comminuted cooked product, they must be shipped

under seal like all other restricted product. However, if the boned, boxed meat from these carcasses is properly packaged and labeled "Boar Meat for Use in Comminuted Cooked Product Only," shipping under seal is not necessary. Restricted boar meat properly packaged and labeled this way is the only exception to the rule that restricted products must be shipped from one establishment to another under seal.

For review purposes, the following chart lists those conditions that the veterinarian may pass with a restriction, the regulation reference and the specific restrictions.

CONDITION	**REG.**	**FREEZING (15 F) Days: 10-carcass 20-boxed**	**COOKING 170 F/ 30 min.**	**HEATING 140 F**	**COMM. COOKED PRODUCT**
Beef Measles	311.23	X		X	
Sheep Measles	311.25			X	
Pork Measles	311.24		X		
Tuberculosis	311.2		X		
Caseous Lymphadenitis	311.18		X		
Parasites (not transmissible to humans)	311.25		X		
Sexual Odor Of Swine	311.20				X
Eosinophilic Myositis (EM)	311.35				X

Trichinosis

Trichinosis is a disease in humans that may be contracted from swine carcasses infested with the parasite *Trichinella spiralis*. Some pork products are treated to destroy trichinae. These pork products, however, are not considered as passed with a restriction. Trichinae control in the U.S. relies on consumer education. That is, all pork muscle products are considered potentially contaminated and must be thoroughly cooked before being eaten.

FSIS regulations state that all pork products having the appearance of being ready-to-eat must be treated to destroy trichinae before leaving the establishment. Regulation 9 CFR 318.10 describes in detail acceptable methods that may be used to destroy trichinae. The three methods currently approved for treating pork for trichinae are:

Heating
Refrigeration (Freezing)
Curing

Irradiation (gamma irradiation) is also approved for trichinae control. However, it is considered to be an "additive" rather than a treatment.

Certain pork products have been exempted from the requirement that they be treated to destroy trichinae. They include:

Pork hearts, stomachs, and livers.
Pork products that will normally be cooked sufficiently in the home, such as fresh pork, bacon, jowls, and unsmoked fresh sausage.
Pork from carcasses or carcass parts that have been analyzed by an approved laboratory and found free of trichinae.

As a safety factor, inspection personnel should consider all pork to be potentially contaminated with trichinae. This is why pork products must be kept separate from meat products of all other species.

Condemned and Inedible Products

Condemned product is product that has been determined through inspection to be diseased or having a condition that renders it unfit for human consumption. It is prohibited from entering commerce for use as human food (9 CFR 314, 318.95).

Inedible product is any product that is adulterated, uninspected, or not intended for use as human food. The term inedible refers to product that by its nature is not handled as human food (9 CFR 301.2). Examples include bones, uncleaned intestines, lungs, reproductive organs, feet, etc. If inedible product is diseased or has the appearance of edible product, it must be handled as condemned.

Both condemned and inedible products are not fit for human consumption. Due to the edible appearance of condemned product, its control is most crucial and the requirements found in the regulations are very specific. Edible product may have a similar appearance to condemned product and some inedible product.

Principles of control

FSIS control of condemned and inedible product involves five principles:

1. Identification
2. Custody
3. Separation
4. Destruction
5. Documentation

FSIS personnel must monitor the establishment's handling procedures of condemned and inedible product to assure that it is properly identified, maintained in custody, kept separate from edible product, and properly destroyed. Additionally, all actions taken must be appropriately documented.

Identification

As has been discussed, condemned products may look edible. For this reason they must be properly identified. The regulations require that each condemned carcass, part,

or visceral organ be marked with the "U.S. Inspected and Condemned" brand (9 CFR 312.6(a)(5)). If the condemned product cannot be branded because of its size or texture, it must be placed in a container identified with the words "U.S. Condemned." Condemned product is to be disposed of by tanking.

An exception in the regulations allows the salvage of certain classes of condemned product for the production of products for purposes other than human food, including pet/animal food (9 CFR 314.11). One example is beef livers condemned for human consumption but allowed for use in pet food. The system used to identify product that is condemned versus product that is allowed for animal food must be consistent.

Custody

The FMIA requires that the inspector be able to certify that all condemned product is properly destroyed. To assure this, security of condemned product is essential. The regulations state that all condemned product must be kept in custody (security) of inspection personnel until it is destroyed for human purposes on or before the close of the day on which it was condemned. Destruction can be accomplished by incineration, rendering (tanking), or denaturing (9 CFR 314.1, 314.3).

Organs and parts (e.g., stomachs, intestines, bones, feet) may be saved for edible (human) food at some establishments. Others may save these organs and parts as inedible product for products for purposes other than human food, including pet/animal food . This is permitted provided that the establishment properly identifies the organs and parts. If the organs and parts are not used for either purpose, the product doesn't require any special security if kept separate from edible product. If it is shipped off premises for rendering, the product doesn't require denaturing as long as the establishment's handling of the product results in an inedible appearance (e.g., denaturing). Hair, hide, horns, and hooves of any animal are products considered naturally inedible. It is not necessary to require special identification or denaturing, but they must be kept separate from edible product.

Separation

Condemned and inedible products must be kept separate from edible products. A physical separation of edible and inedible facilities must be maintained to avoid cross-contamination, (time or space). Contamination of edible products with materials from inedible and condemned product has potentially grave public health consequences. Inedible containers brought into edible departments must be watertight, acceptably clean, and properly identified. There are two types of inedible product containers. Containers for product condemned to tankage are marked "U.S. Inspected and Condemned." Those for product condemned for human use (inedible) but eligible for pet animal food are identified as "Inedible."

Bile historically has been regarded as inedible and when contamination of edible product occurs it must be removed before completion of inspection by FSIS personnel. There are provisions allowing that inedible bile can be saved for manufacturing uses and stored in edible product areas. Where it is allowed, bile must be segregated, handled, and labeled as an edible product.

Destruction

There are three basic methods approved for making condemned and inedible meat products incapable of being used as human food. They are:

Rendering (9 CFR 314.1)
Incineration (9 CFR 314.3)
Application of approved denaturants (9 CFR 314.4)

Inedible rendering is a process by which materials are heated sufficiently to destroy them for human food. When the establishment has its own facilities to perform the rendering process this is termed "on-premises" rendering. Many establishments do not have such facilities. Instead they may ship condemned and inedible materials to an outside rendering facility. This is referred to as "off-premise" rendering.

Tanking is when condemned product is placed in a rendering tank under the supervision of an inspector who would then seal the tank. Once the contents are heated adequately to destroy them for human purposes, the inspector will then remove the seal, thereby releasing it from his/her custody. This method is rarely, if ever, used today. Establishments that perform their own "on-premises" rendering today generally utilize hashers and/or pre-breakers as a pre-tanking preparation of condemned product. This gives an inedible character and appearance to the product. For this reason, custody is not necessary once the material has been hashed. In addition, there is no requirement to use denaturant on this product to be rendered on-premises. However, prior to hashing, custody of the product must be maintained.

Whenever condemned materials are to be shipped to another site, they must be properly denatured. This is true whether the material has been hashed or not. Since no inspection personnel will oversee the denaturing process at non-federally inspected facilities they will not use any official device to seal the containers or vehicle.

If the establishment doesn't have inedible tanking facilities and it does not send condemned product for off premises rendering, all condemned product must be destroyed (under inspector custody) by incineration or by the application of an approved denaturant. Denaturants change the color and/or odor of products sufficiently to destroy them for food purposes.

Line Speeds

Maximum line speeds established by FSIS are permitted on the eviscerating line when optimum conditions exist (9 CFR 310.1). When there are less than optimum conditions, line speed adjustment is required. The IIC is responsible for directing establishment management to reduce the line speed to permit adequate inspection. When the IIC is satisfied that the situation that necessitated the line speed reduction has been corrected, he or she will permit increase in the line speed. The IIC may require the establishment to adjust line speed to a slower rate for deficiencies in presentation by the establishment or if the health condition of the animals is such that it requires more extensive inspection.

Marks of Inspection

Once the carcass and parts have been passed for inspection, the carcass may be washed, branded, and sent to the cooler. For livestock carcasses, the marks of inspection are applied just prior to the carcass entering the cooler. Each carcass must contain at least one mark of inspection on each half before entering the cooler if the carcass is completely split in half. If the sides of the carcass are held together by natural (skin) attachments, one mark of inspection is sufficient. The marks of inspection for meat products are shown in 9 CFR 312. FSIS Directive 6810.2 covers marking meat carcasses and products. **Exception: per FSIS Notice 02-14, "Verification of carcasses that an establishment further processes without an official inspection legend" (1/8/14)**

The Agency intends to revise its regulations to remove the requirement that carcasses bear the mark following inspection on the slaughter floor if the carcass is to be further processed in the establishment. Pending this rulemaking, inspection program personnel are to allow inspected and passed carcasses to leave the slaughter floor without being marked if:
1. the establishment requests that they not be marked;
2. the establishment further processes the unmarked carcasses at the establishment; and
3. the establishment maintains control of the carcasses in the manner described in part III of this notice.

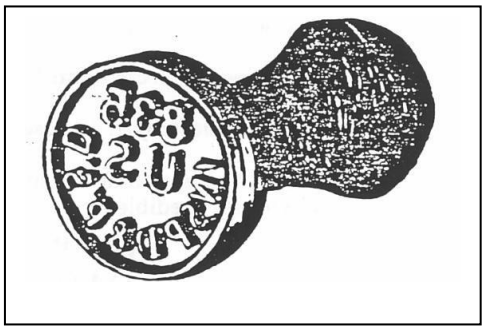

Postmortem Reports

Inspection personnel must also record information about the number of animals slaughtered, the number and types of products condemned, and other details. The types of reports required are described in FSIS Directive 6200.1. The IIC is responsible for completing FSIS postmortem forms. He or she may request input from you in order to complete the required information.

APPENDIX

EXAMPLES OF BYPRODUCTS

CATTLE – SOME EDIBLE OFFAL PARTS (Byproducts)

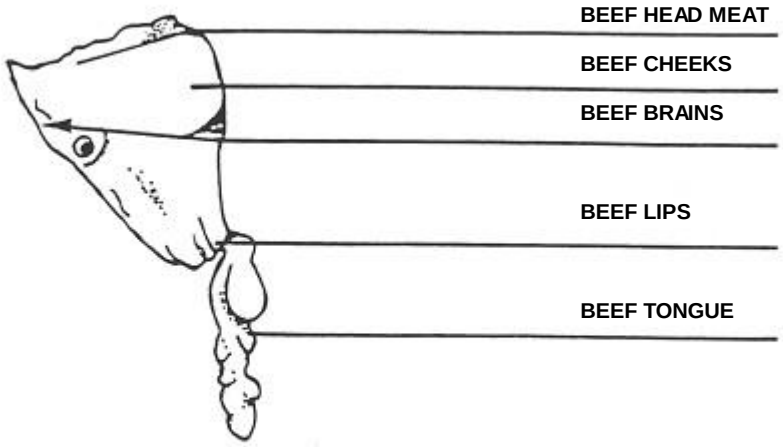

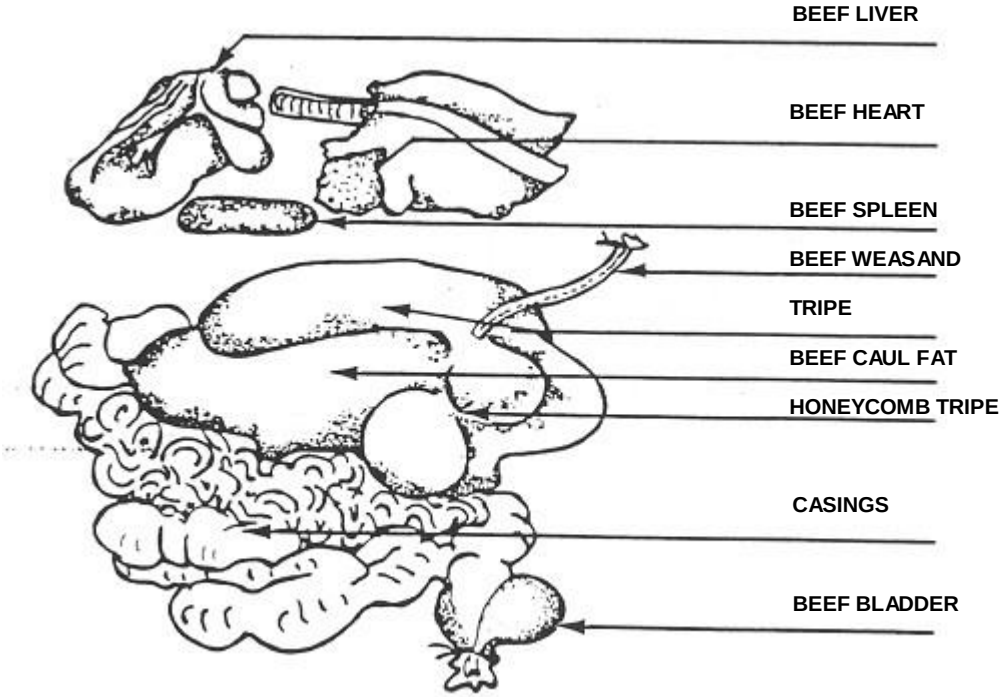

PORK BYPRODUCTS

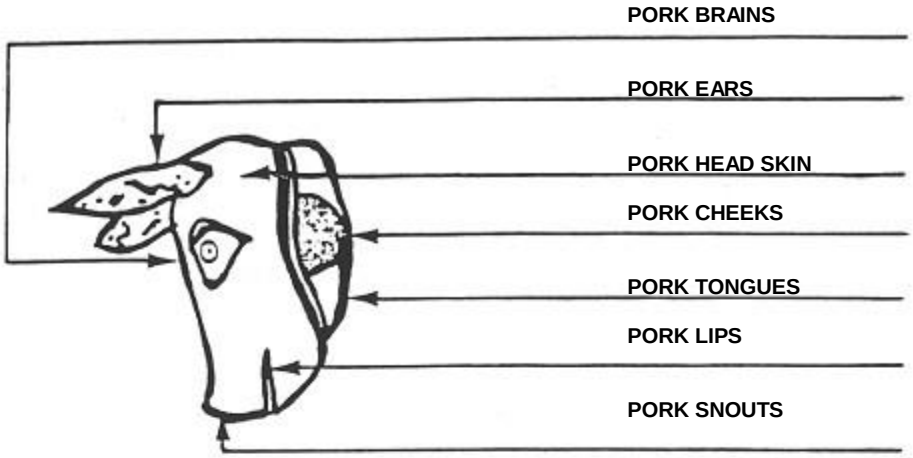

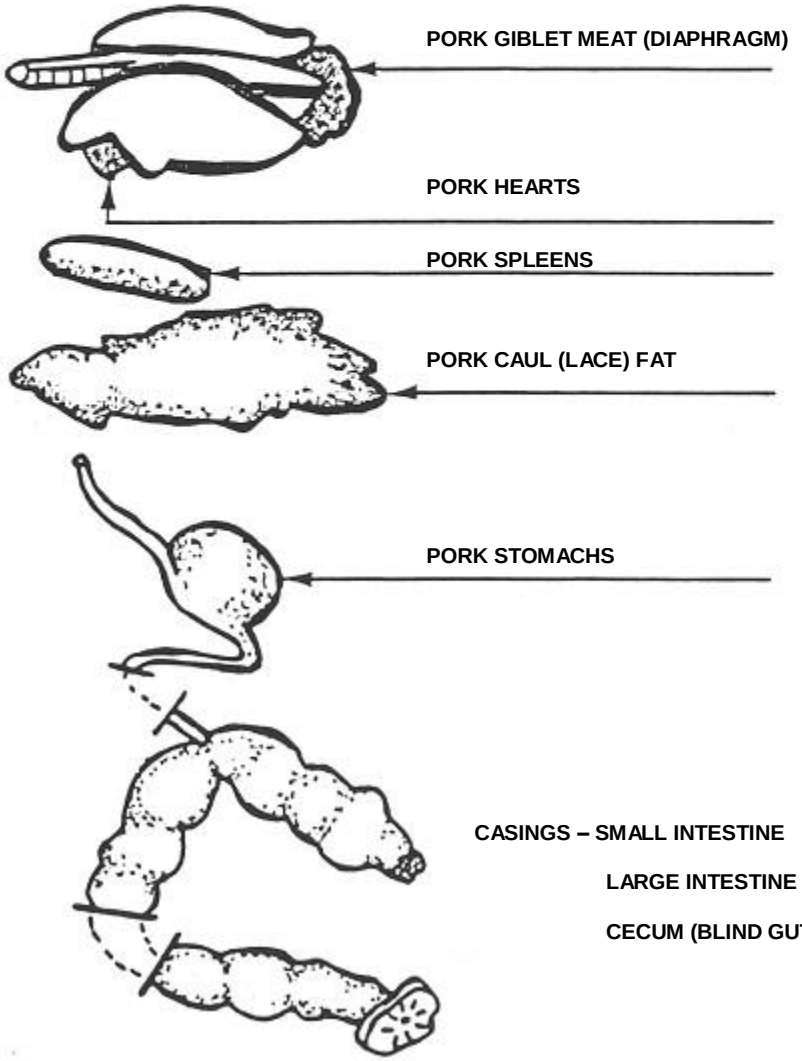

PORK BYPRODUCTS

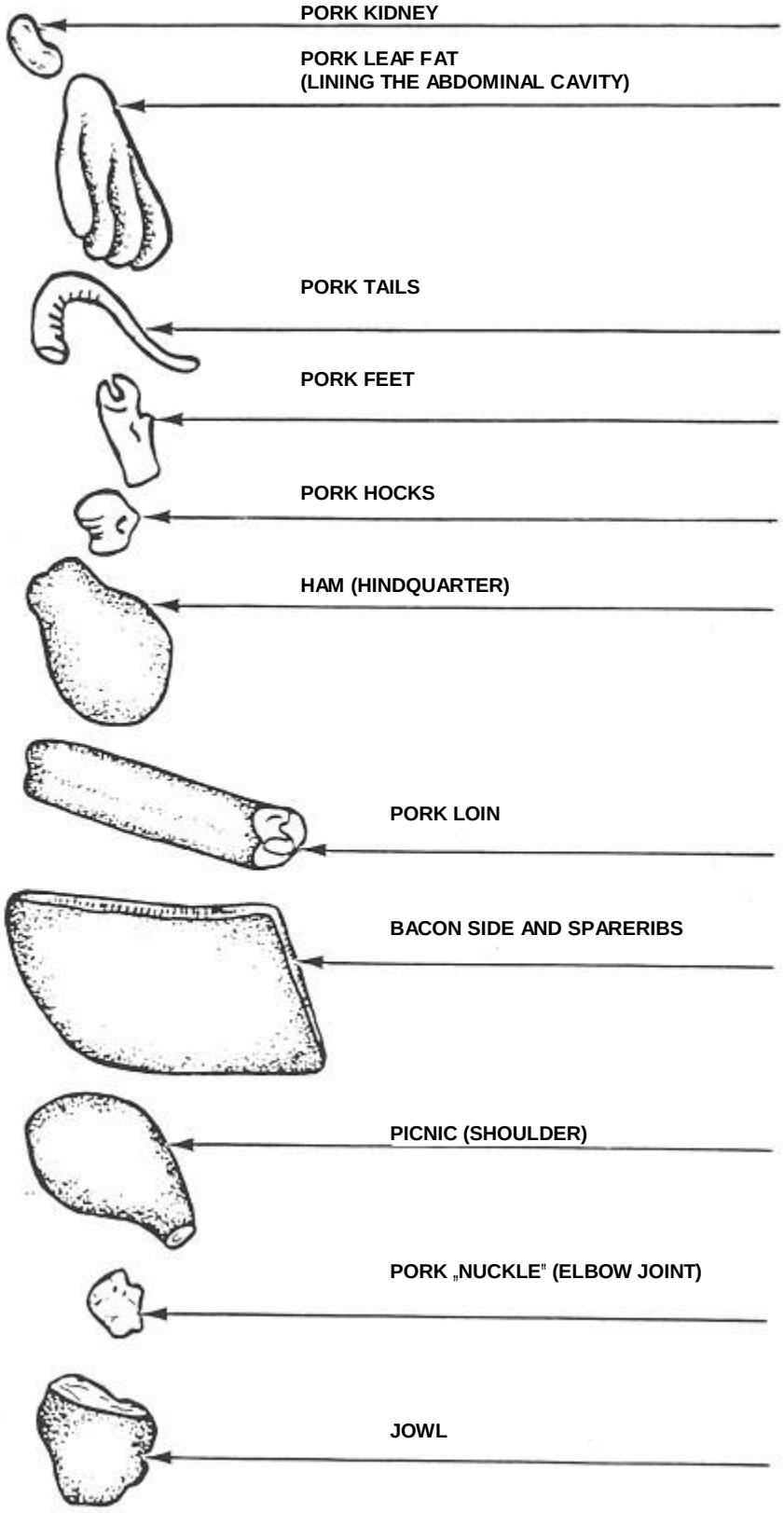

Calf Inspection

Calves of all sizes and ages are slaughtered. Some establishments slaughter "bob veal" calves. These calves are defined as "under 150 pounds and less than three weeks of age". Other establishments slaughter "veal" calves which are considered to be less than 400 pounds with a non-functional rumen. There are some aspects of bob veal operations which you should be aware of. Historically, these very young calves have been a serious source of residue violations, particularly sulfa residues. Because of this, much of the work in establishments that slaughter bob veal calves involves the use of rapid in-plant tests to detect sulfas and antibiotics. The KIS test is used to detect residue violations. Should you be assigned to a bob veal operation in the future, become familiar with the statistical sampling plans and tests used.

Inspection procedures for calves are not nearly as complete as those for mature cattle. It is important to note that large calves require an expanded inspection procedure that is identical to that for cattle inspection. This is because some abnormal conditions, such as measles (cysticercosis), require a certain amount of time to develop. If in doubt about whether to use calf or cattle inspection procedures, it is essential to check with your supervisor to assure you perform the appropriate procedures.

Calves are dressed by one of two methods. Calves may be hot skinned. This method is essentially the same used for other livestock. The hide is removed on the kill floor at the time of slaughter. Alternatively, calves may be cold skinned. This is also referred to as dressed "hide-on." In this method the hides are not removed on the kill floor but rather in the cooler after the carcasses have chilled. It is said that cold-skinned calves maintain their "bloom" (the bright red appearance of freshly dressed, properly chilled carcasses and meat) and shrink less than hot-skinned calves. This is because the hide prevents loss of moisture from the carcass during chilling, resulting in less weight loss.

Hot skinning

The same basic sanitary dressing requirements that apply to cattle are applicable to hot-skinned calves. They include:

- Daily cleaning of the knocking box.
- Keeping the animals as dry as possible.
- Not bleeding in the dry landing area if possible.
- Clean head skinning and removal (head with carcass identification).
- Sanitary hide and feet removal.
- Bung and bladder tying as necessary.
- Sanitizing brisket opening device between each use

Establishment management is responsible for handling all carcasses and parts in a sanitary manner regardless of the dressing method used.

Cold Skinning (Hide On)

The carcass (hide) must be completely clean of dandruff, dirt, and fecal material before heading or opening of the carcass. Cleaning is sometimes facilitated with "curry combs"

or other scraping instruments, and always with potable water. There needs to be sufficient water pressure, volume, and a competent washer to accomplish complete cleaning. There is one exception to the rule that cleaning of the hide must precede heading or opening of the carcass. Should you ever be assigned to an establishment where kosher slaughter is performed, you will note that the head may be removed before the hide is washed.

Monitoring the spacing of carcasses is a very critical point. After removal from the carcass, the head is thoroughly washed and the cavities flushed in the same manner as cattle heads (this is true of hot-skinned calves also). The head is then placed on a rack or hook for inspection. As in other species, when the head is removed from the carcass a method of identification acceptable to the IIC is necessary to assure that the identity of the head and its corresponding carcass is maintained until inspection is complete.

Some establishments may wish to save calf tongues but do not want the rest of the head and therefore do not want to expend the effort to skin the head. This is acceptable provided:

The head is washed,
Medial retropharyngeal (suprapharyngeal) lymph nodes are exposed for inspection, and,
Tongues are washed individually.

The hide is then opened and skinned back on the hock just far enough to allow insertion of the gambrel. The lower leg with the hide attached can then be removed. The front side of the hock should not be skinned until the hide is completely removed. *The hock is not to be exposed until final skinning.*

Next, the front feet are removed. Note that all procedures to this point have been performed prior to any opening being made in the carcass.

Brisket splitting, bung dropping, belly opening, and evisceration must be consistently done in a sanitary manner. Splitting the brisket may be done with a knife, saw, or other acceptable instrument. Whatever device is used, it must be sanitized following each use. The person opening the belly must take care to prevent unnecessary contamination of the carcass.

Bung tying in large calves is done as in cattle, i.e., the bung and bladder must be tied before evisceration unless the urinary bladder is removed and the bung does not cause contamination. The procedure in small calves is similar to that in sheep. The bung and bladder are grasped and the large intestine preceding the bung is stripped. The bung is severed and the bung and bladder are removed.

Now the carcass is ready to be eviscerated. Following evisceration, the viscera (abdominal viscera and pluck) are placed into a tray or truck for inspection.

Hot skinned calves

A. Head Inspection

1. Observe head's surfaces.

2. Incise and observe medial retropharyngeal (suprapharyngeal) lymph nodes - left and right.

B. Viscera Inspection

1. Observe and palpate lungs' lymph nodes [tracheobronchial (bronchial) and mediastinal], costal (curved) surfaces of the lungs, and the heart.
2. Turn lungs over and observe ventral (flat) surfaces.
3. Observe spleen.
4. Observe and palpate dorsal surface of liver.
4. Turn liver over, observe ventral surface, and palpate hepatic (portal) lymph nodes.
5. Observe stomach and intestine.

C. Carcass Inspection

1. Observe outer and cut surfaces.
2. Lift forelegs and observe neck and shoulders.
3. Observe body cavities.
4. Observe and palpate medial (internal) iliac lymph nodes and kidneys.

Cold Skinned (Hide On)

In addition to the above inspection procedures, inspection procedures of "hide-on" carcasses must include observation of the hide for contamination, parasitic conditions and other abnormalities, and palpation of the back for grubs. The skins of bruised calves and those affected with grubs, lice, warts, ringworm, and other skin conditions, as well as those found unclean, must be removed as part of the dressing operations at the time of slaughter. In all cases, skinning of calves must be done in a sanitary manner and unskinned carcasses must be adequately spaced.

Large Calves

Recall that large calves require the same inspection procedure described for cattle. This expanded procedure is necessary on large calves because their age may have permitted abnormal conditions such as measles (*Cysticercosis*) to develop. Improper presentation of carcasses or viscera (such as dirt, hair, hide, ingesta, grease, pus, etc.) may occur as in other species. When this occurs, action must be taken by the inspector to correct the problem. Actions taken will depend on the nature and frequency of dressing errors. If in doubt about what actions need be taken, review the cattle and swine inspection modules for assistance.

Calf Postmortem Pathology

When abnormal conditions are encountered on calf inspection, the proper reaction is to retain the carcass and parts for veterinary disposition, or retain just the carcass if only hide removal and/or extra trimming is necessary for the carcass to pass inspection. A two-section retain tag is usually used by placing one section on the carcass and one on the viscera if the carcass, head, and viscera are retained. The corresponding head is retained by use of the head-carcass house identification tag. If only the carcass is retained, both retain tags should be placed on the carcass. The large retain tag (US Retain/Reject tag) may be used to retain carcasses for dirty hides. Should you be

assigned to a calf slaughter establishment you must become familiar with whatever means is utilized to identify retained carcasses and parts.

Calves are subject to disease and abnormalities as in other species, while some are unique to calves. A few examples of abnormal conditions that might be encountered include:

Abscesses

Pneumonia

Nephritis

Ringworm - This condition should be detected on ante mortem inspection. It is significant in hide-on calves and would require removal of the hide at the time of slaughter.

Warts - See Ringworm.

Grubs - Another hide condition that requires skinning the carcass. Grubs are the larvae of the heel fly, which infects cattle. The primary reason for palpating the backs of calves at postmortem inspection is to check for the presence of these parasites.

Arthritis

Icterus - The carcass and parts have a yellow appearance. In true icterus, normally white tissues (such as the tendons and sclera of the eye) are affected.

After carcasses are cold-skinned in the cooler, they must be examined for injection lesions, foreign bodies, parasites, bruises, or other pathology not detectable with the hide still on.

Sheep and Goat Inspection

Viscera Inspection for Sheep

1. Observe abdominal viscera, esophagus, mesenteric lymph nodes, and omental fat.

2. Observe bile duct and content and express gall bladder.

3. Observe and palpate liver (both sides) and costal surfaces of lungs.

4. Palpate bronchial and mediastinal lymph nodes.

5. Observe ventral surfaces of lungs.

6. Observe and palpate the heart.

When certain disease conditions are found, the viscera and carcass will be retained for the veterinarian's final disposition. The usual procedure for tagging is to use two small retain tags, each having identical serial numbers. One tag is attached to the viscera, and the other tag to the leading side of the carcass on the hind leg.

When an unacceptable or improper presentation occurs, you must evaluate the situation and require the establishment to take action you consider necessary. For example, a sheep pluck covered with paunch content is presented to you for inspection. You have been working the assignment all day and this is the first incident to occur today. You would delay your inspection of that pluck until it was cleaned up adequately for inspection. However, it the same situation was occurring frequently, you would have to stop the line and inform establishment management the problem had to be corrected.

Carcass and Head Inspection for Sheep

1. Observe outer surfaces of carcass, body cavities (pelvic, abdominal, thoracic), and spleen.

2. Observe and palpate kidneys.

3. Palpate subiliac, scrotal or mammary, and deep popliteal lymph nodes.

4. Palpate back and sides of carcass.

5. Palpate superficial cervical lymph nodes and shoulders and lift forelegs.

6. Observe neck, shoulders, and head.

For lamb carcasses, FSIS Directive 6100.2 gives the required inspection procedures as:

Viscera Inspection for Lamb

1. Observe abdominal viscera, esophagus, mesenteric lymph nodes, and omental fat.

2. Observe bile duct and content, and express gall bladder.

3. Observe and palpate liver (both sides) and costal surfaces of lungs.

4. Palpate bronchial and mediastinal lymph nodes.

5. Observe ventral surfaces of lungs.

6. Observe and palpate the heart.

7. Examine the pancreatic gland for wholesomeness if the gland is saved for edible purposes. Tapeworms in the bile duct indicate possible infested pancreatic gland.

Carcass-Head Inspection for Lamb

1. Observe outer surfaces of carcass.

2. Observe pelvic, abdominal and thoracic body cavities.

3. Observe spleen and kidneys.

4. Observe neck, shoulders and head.

Following are some of the more common disease conditions in sheep.

Caseous lymphadenitis – a bacterial infection results in a disease that produces inflammation and resulting caseous (cheese-like) abscesses in lymph tissue. Retain for veterinary disposition.

Tapeworm - a parasite found in the gall bladder and bile ducts (and occasionally pancreatic ducts). Livers affected with this parasite are condemned for human food; may be salvaged for pet food as an inedible product, provided they are properly handled.

Nodular worms (*Oesophagostomum* species) – a parasite that produces pea-sized firm nodules on the surface of the small and large intestine, may be associated deterioration of the carcass (thinness, a poor carcass, or an otherwise run-down condition). Retain for veterinary disposition.

Thin-necked bladder worm - large (3/4 inch or 2 cm), fluid-filled, clear cysts, usually attached to the surfaces of the liver, intestines, mesentery, and omentum. They are

frequently also seen in the pelvic cavity. May take the form of an active (live) larva (clear soft cyst membrane and clear fluid contents) or may be degenerated (dead) and appear as firm nodules with a scar tissue or calcified consistency. Condemn organs affected with this parasite and have the pelvic cavity trimmed of any affected tissues, again after correlating with your supervisor.

Sheep measles (*Cysticercus ovis*) – a parasite is similar to the measles found in cattle because it is found in muscle tissue such as the heart, diaphragm, esophagus, or carcass. The cysts are small (about 1/4 inch of 0.6 cm) and may appear as active, clear fluid-filled cysts or the degenerated firm nodules as described above for the bladder worm. Retain for veterinary disposition.

Hydatid cysts – cysts are approximately 2-4 inches (5-10 cm) in diameter and may be multi-compartmented, with a white, thick-walled cyst membrane that contains an amber, clear fluid that may contain sand-like granules. Occasionally, this thick white membrane will have a very slight clearing of the cyst wall, making it almost transparent. The cysts are most often seen in the lungs and/or the liver. The affected tissues must be condemned to tankage and never allowed for use in pet foods as is allowed with other parasitized product (9 CFR 314.10(a)).

"Sarco" (*Sarcosporidiosis* sp.) - flat, white parasitic cysts are imbedded in muscle tissue (esophagus, heart, carcass, etc.), having a "rice grain" appearance and being "cigar-shaped bodies" about 1/4 inch (0.5 cm) long. Retain the carcass for veterinary disposition.

Neoplasia, tumors - growths that can be bizarre or subtle changes of size and/or color of tissues and organs. Retain the carcass and parts for veterinary disposition.

Pneumonia - an inflammatory disease in which the normal soft "foamy consistency" feel of the lungs and their normal "light-pinkish" color is changed. The color change may vary from a bright red, to reddish-brown, to brown, to gray, to white. The change in the consistency or feel of the lung may vary from the normal "foamy feeling" to firm (slightly or moderately or markedly). These changes may be accompanied by the occurrence of abscesses in the lung tissue itself or in the lung's lymph nodes. Retain the carcass for veterinary disposition.

Nephritis - kidneys appear enlarged (swollen) or may be partially shrunken with a gristle-type scar tissue in the kidney tissue. Abscesses may be present. Petechiation, a hemorrhage from a small blood vessel, may be observed. The color change may vary from the kidney's normal color to pink, to blood red, to brick-red, to yellow or amber, to dark brown, to almost black. Various-colored radiating streaks can sometimes be seen on the kidney's surface in certain disease states. Retain for veterinary disposition.

Abscesses - when this condition is localized, condemn the affected area and pass the reminder of the carcass. However, when it is not localized, retain the carcass and viscera for veterinary disposition. When an abscess has been cut into or opened, there is a real possibility that other parts of the carcass have been contaminated by this pus. Carcasses so contaminated must be trimmed to your satisfaction before you allow it to pass. If the establishment can accomplish this with

a minimum of interference to their operations and you find their solution acceptable, you can allow operations to proceed; however, if not, you must delay your inspection (or stop operations if necessary) until the problem is corrected.

Arthritis - inflammation of the animal's joints. These are often infected and should not be opened (cut into) on the line. The affected joints will be enlarged and regional lymph nodes generally also are enlarged and may be discolored. Several joints may be involved (polyarthritis), particularly in lambs. Other disease conditions may complicate arthritis, such as septicemia, toxemia, or pyemia. Retain for veterinary disposition.

Emaciation - fat tissue loses its normal white color and semi-firm consistency and becomes a darker color (almost brown), with a jelly-like to fluid-like consistency. Fat around the heart seems to be the first area of the body affected. Retain for veterinary disposition, but if only the fat around the heart is affected, don't retain the carcass and viscera.

All localized conditions like bruises, contamination, adhesions, etc., are to be removed by an establishment employee before the carcass enters the cooler. An exception is made in the case of "wild oats," otherwise known as "needle grass or grass awns." These are slender barbed bristles that are a part of the cereal grasses, which become embedded in the subcutaneous tissues of sheep as they graze on pasture. They are black or brown wooden-like slender awns about one-half the size of a wooden toothpick when seen on the carcass. They often can be seen but usually are readily palpable. They are not noticeable on the live animal. They are found generally in the subcutaneous tissues over the abdomen (belly) and the thorax (chest) and occasionally on the back and legs. They are found only in certain parts of the country and therefore most lots are totally unaffected. When they are encountered on the production line the carcasses are trimmed, but when they are trimmed depends on how extensively the carcasses are affected and the proportion of carcasses in the lot affected and the establishments' history of cooperation in correcting the problem. If many of the carcasses (a high proportion) are affected and/or those affected carcasses have numerous grass awns in the tissues, FSIS will allow these carcasses to go into the cooler and be trimmed after cooling if the establishment will segregate or group all affected carcasses in one cluster. Further, if the establishment does not cooperate in this provision, then they must trim all affected carcasses in the presence of the FSIS inspector and before each carcass is passed. If there are just a few grass awns on affected carcasses and only a few (a low proportion) of these affected carcasses in the lot, the establishment should trim affected carcasses before they enter the cooler.

This module has not referred specifically to the slaughter and inspection of goats. Since the requirements and inspection procedures in goats are identical to those of sheep, the information on sheep contained herein can be extrapolated to goats. Refer to FSIS Directive 6100.2 Post-Mortem Livestock Inspection for goat inspection procedures.

Knife Sharpening

A sharp knife is absolutely essential for efficient and safe performance of postmortem inspection duties. Sharpening a knife and maintaining its sharpness continuously is simple when you have basic knowledge of knives, whetstones, and steels, combined with practice using each of them.

Safety is important in the use of knives. A dull knife, in addition to being ineffective for correct incising, is a safety hazard because the user must apply increased effort and tends to -pushll the knife through the tissues. A sharp knife can dull quickly after hitting a bone or a metal rack. You can tell that your knife is dull when the knife stroke is rough and you want to -sawll through the tissues rather than slice them cleanly. The cut edges from a dull knife are ragged and uneven. Do NOT use a dull knife. When your knife is dull, request a sharp one.

At the establishment, you will learn all the appropriate knife sharpening techniques.

Cattle Inspection Workshop

1. Which of the following conditions is most likely to be detected by observation (without slicing or palpation) of the head?

   a. Epithelioma (cancer eye).
   b. Tuberculosis (TB).
   c. Eosinophilic myositis (EM).
   d. Cysticercosis (tapeworm).

2. In which of the following head tissues are lesions of eosinophilic myositis (EM) usually found?

   a. Eye and orbital tissue.
   b. Masseter (cheek) muscles.
   c. Skin and tonsils.
   d. Lymph nodes.

3. Which of the following statements best describes the usual action taken by the head inspector upon detection of abnormal conditions that might be associated with a disease condition?

   a. Condemns the head.
   b. Asks establishment employee to identify the proper carcass for the carcass inspector's special attention.
   c. Assures that the head and corresponding carcass are identified with retain tags and held for veterinary disposition.

4. The "measles" found in cattle are in reality:

   a. Lesions of grub infestation.
   b. Lesions of tuberculosis in muscle tissue.
   c. Tapeworm cyst in muscle tissue.
   d. Lesions of eosinophilic myositis.

5. During cattle head inspection, actinobacillosis is sometimes found in the lymph nodes. Where else can actinobacillosis be found during cattle head inspection?

   a. Paunch.
   b. Tongue.
   c. Eye.
   d. Teeth.

6. Cattle Head Inspection Procedures

   A. List the four basic steps of cattle head inspection

      (1) _____

      (2) _____

      (3) _____

      (4) _____

7. Observation of the head

   A. List four instances of improper presentation.

   a. c.

   b. d.

   B. List two pathological or abnormal conditions that may be detected when observing the head.

   a. b.

8. Supply information as indicated.

   a. Epithelioma

      Usual site of lesions –

   b. Actinomycosis

      Usual site of infection -

   c. Actinobacillosis

      Usual site of infection -

   d. Tuberculosis

      Usual site of infection -

   e. Neoplasm (malignant lymphoma)

      Usual site of lesions –

f. Cysticercosis

Usual site of infection -

g. Eosinophilic Myositis

Usual site of infection -

h. Pleuritis

Usual site of infection -

i. Pneumonia

Usual site of infection -

j. Flukes

Usual sites of infection -

k. Pericarditis

Usual sites of lesions -

l. Enteritis

Usual site of infection -

9. A liver showing five pinpoint sawdust lesions on one end may be passed for food without restriction. (Circle your answer.)

   a. True

   b. False

10. Select the proper disposition of a liver showing numerous sawdust lesions that are confined to less than 1/2 of the liver.

   a. It must be condemned in its entirety.

   b. The affected portion of the liver must be removed and condemned. The remaining portion may be passed for food.

   c. The entire liver must be condemned, but may be salvaged for animal food.

   d. None of the above.

11. A liver with numerous "Telang"" lesions

    a. may be passed for food after removal of the lesions.

    b. must be condemned, but may be salvaged for animal food.

    c. may be passes for food without restriction.

    d. none of the above

12. One of the following conditions requires that the entire liver be condemned, and ineligible for use as an animal food.

    a. Carotenosis

    b. Benign abscess

    c. Hydatid cyst

    d. Flukes (Distoma)